

ASSOCIATION OF DOUBLE ELEVATOR PALSY WITH JAW WINKING PTOSIS

MUHAMMAD MOIN¹ FRCS, FRCOphth,

Postgraduate Medical Institute / Ameer ud Din Medical College, Lahore

Correspondence: 37 Shadman Colony I, Lahore 54000, Pakistan. Email: mmoin7@gmail.com

ABSTRACT

Purpose: To determine the association of double elevator palsy with jaw winking ptosis.

Study Design: Interventional case series.

Place & Duration of Study: Mayo Hospital, Lahore between 2000 and 2003 by one surgeon.

Material & Methods: Seventy patients with congenital ptosis were managed with Frontalis Fascia lata sling Surgery with or without vertical muscle surgery. Pre-operative visual acuity, margin to reflex distance in primary gaze (MRD₁), margin to reflex distance in down gaze (MRD₂), levator function, extra-ocular movements, bell's phenomenon and jaw winking phenomenon were noted in all cases. Post-operative MRD₁, MRD₂, lagophthalmos and corneal surface were also noted.

Results: Review of 70 cases with congenital ptosis showed that 8 (11%) patients had jaw winking ptosis and 10 (14%) patients had double elevator (DE) palsy. Out of these 8 patients with jaw winking ptosis, 4 (50%) patients had DE palsy. Thus 6% of the total patients had both jaw winking ptosis and DE palsy.

Conclusions: This study shows that we must be very careful to eliminate double elevator palsy in cases of jaw winking ptosis due to their strong association

Key Words: Double Elevator Palsy, Jaw Winking, Ptosis,

INTRODUCTION

Jaw winking was first described by Marcus-Gunn¹ in a 15 year old girl in 1883. It is the association of unilateral congenital ptosis with retraction of ptotic lid on ipsilateral pterygoid movement. Bilateral cases have been observed but are rare. Congenital misdirection of the fifth cranial nerve into the third cranial nerve innervating the levator has been postulated². Jaw winking does not objectively improve with age^{3, 4}. Surgery is considered in such cases if there is cosmetic problem or ptosis is marked. Association with double elevator palsy (DE) has been reported as 75 %⁵, 25%⁴ and 8.3 %⁶ in literature.

Double elevator palsy is characterized by hypotropia of the paretic eye in primary gaze, by a limitation of elevation in abduction and adduction, by a negative forced duction test and by presence of Bell's phenomenon. It often requires additional procedure to correct the hypotropia before management of jaw winking. We report our findings in 4 cases with this double pathology.

MATERIAL AND METHODS

Records of 70 patients with congenital ptosis saved on computer database with pre and post-operative photographs were reviewed. All patients were seen at the institute of ophthalmology, King Edward Medical college / Mayo Hospital, Lahore, Pakistan. Pre-operative visual acuity, margin to reflex distance in primary gaze (MRD₁), margin to reflex distance in down gaze (MRD₂), levator function, extra-ocular movements, bell's phenomenon and jaw winking phenomenon were noted in all cases. Post-operative MRD₁, MRD₂, lagophthalmos and corneal surface were also noted. Only 4 patients had both double elevator palsy and jaw winking ptosis. Out of these 3 cases underwent surgery. All patients underwent unilateral levator disinsertion with plication to the sub-brow periosteum and autogenous frontalis fascia lata sling. The third case underwent 5 mm inferior rectus recession to correct hypotropia before frontalis suspension procedure.

CASE 1

A 16 year old girl presented with right jaw winking congenital ptosis (Fig 1 and. 2). Her best corrected visual acuity (BCVA) was 6/36 in right and 6/6 in left eye. Levator function was 4 mm and 15 mm in the right and left eye respectively. She had marked jaw winking measuring about 6 mm. She had 10 prism diopters of hypotropia on the right side with double elevator palsy (Fig 3 and 4). Forced duction test was negative in this patient. The parents decided to undergo only one procedure rather than the preferred procedure to correct the hypotropia first. Post operatively patient had satisfactory cosmetic result with correction of ptosis and marked reduction in jaw winking (Fig 5).

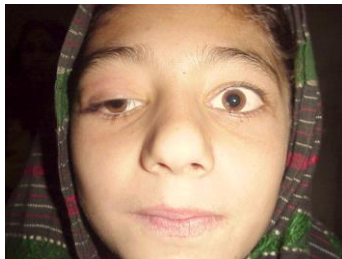

Fig 1: Primary position of gaze

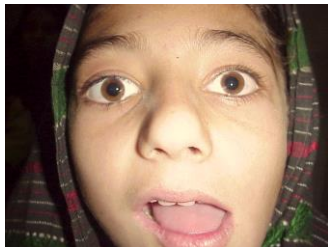

Fig 2: Primary position with jaw open

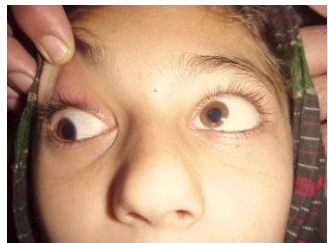

Fig 3: Dextrolevation

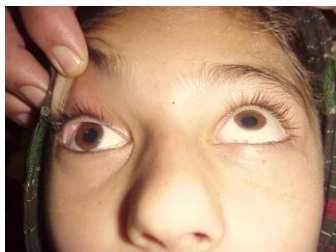

Fig 4: Upgaze

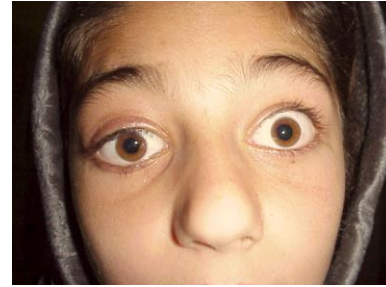

Fig 5. Post-op Rt. Frontalis Sling

CASE 2

A 20 year old girl presented with left jaw winking congenital ptosis (Fig. 6 and 7). Her BCVA was 6/6 in both eyes. Levator function was 17 mm and 6 mm in right and left eye respectively. She had marked jaw winking measuring 6 mm. Left hypotropia of 15 prism diopters and exotropia of 15 prism diopters was noted. Extra ocular movements showed left double elevator palsy (Fig. 8 and 9) and a fair bell's phenomenon. Forced duction test was negative in this patient. Correction of strabismus followed by ptosis surgery was discussed with the patient but the patient agreed for ptosis surgery only. Post operatively there was good elevation of the lid with persistence of exotropia and hypotropia of 15 prism diopters, which was cosmetically acceptable to the family of the patient (Fig. 10).

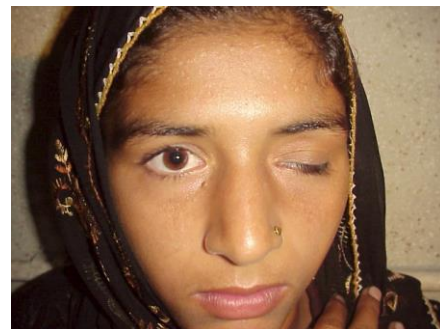

Fig 6. Primary position of gaze

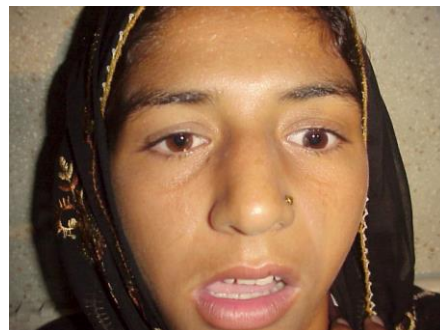

Fig 7. Primary position with jaw open

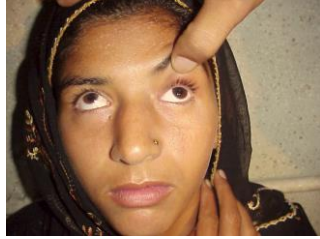

Fig 8. Upgaze

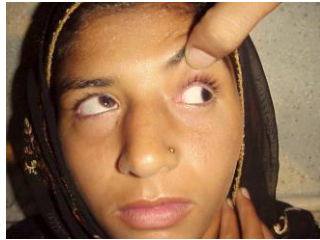

Fig 9. Levoelevation

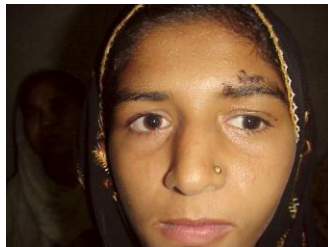

Fig 10: Post-op Lt Fascia Lata Sling

CASE 3

A 20 year old female presented with left jaw winking congenital ptosis (Fig.11) Her BCVA was 6/6 both eyes. Levator function was 15 mm and 4 mm in the right and left eye respectively. Extra ocular movements showed left double elevator palsy (Fig 12 and 13) with fair bell's phenomenon. Left hypotropia of 30 prism diopters and exotropia of 10 prism diopters was noted. Forced duction test revealed inferior rectus restriction. She underwent 5 mm left inferior rectus recession. This improved her hypotropia to 10 prism diopters (Fig 14). Three months later she underwent left frontalis suspension procedure. Post operative results showed good elevation of the lid with reasonable cosmetic improvement (Fig15).

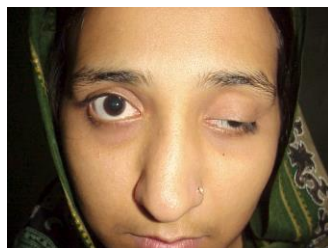


Fig 11: Primary position of gaze

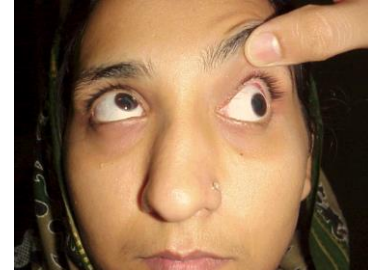

Fig 12: Levoelevation

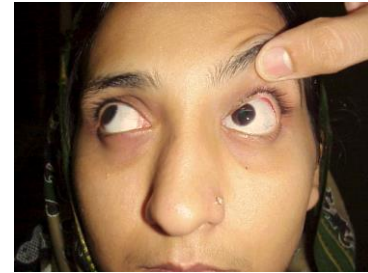

Fig 13: Dextroelevation

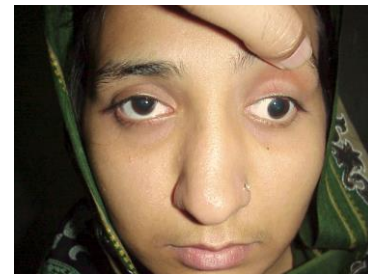

Fig 14: Post-op Lt. Inferior Rectus recession




Fig 15: Post-op Lt Fascia Lata Sling

CASE 4

A 5 ½ year old male presented with right jaw winking congenital ptosis (Fig 16 and 17). His BCVA was 6/18 in the right and 6/6 in the left eye. Levator function was 10 mm and 12 mm in the right and left eye respectively. Extra ocular movements showed a right double elevator palsy with fair bell's phenomenon (Fig 18 and 19). There was hypotropia of 10 prism diopters on the right side. His parents were advised patching of the left eye to correct amblyopia. This was to be followed by squint

surgery and later frontalis suspension procedure but he was lost to follow up.

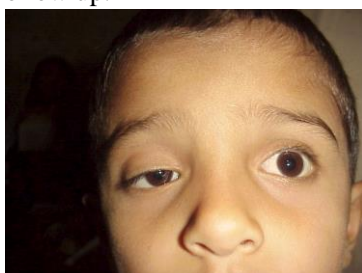

Fig 16: Primary position of gaze

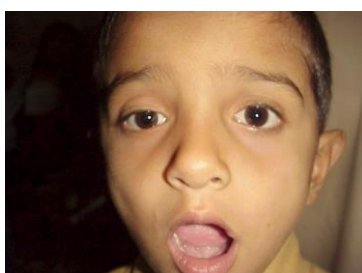


Fig. 17: Primary position with jaw open

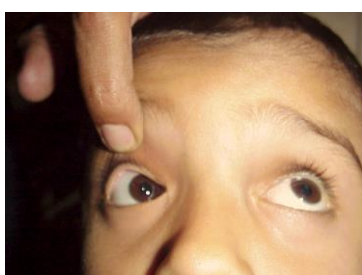

Fig 18: Levoelevation

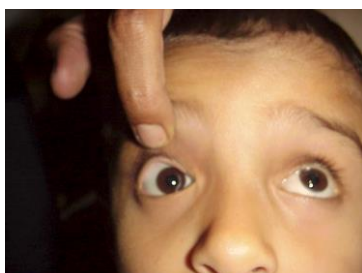

Fig19: Upgaze

RESULTS

In our review of 70 cases with congenital ptosis, 8 (11%) patients had jaw winking ptosis and 10 (14%) patients had double elevator (DE) palsy. Out of these 8 patients with jaw winking ptosis, 4 (50%) patients had DE palsy. Thus 6% of the total patients had both jaw winking ptosis and DE palsy. Male to female ratio was 1:3 in such cases. Three such cases with combined

pathology underwent surgery but the fourth patient was lost to follow up.

<u>Etiology</u>	<u>Cases Percent</u>	
Simple congenital ptosis	52	75 %
Congenital ptosis with jaw wink	8	11 %
Congenital ptosis with DE palsy	10	14 %
Total	70	

Distribution of DE palsy

DE palsy with no jaw wink	6
DE palsy with jaw wink	4
Total	10

DISCUSSION

The etiology of jaw winking is unclear but congenital misdirection of the fifth cranial nerve into the third cranial nerve innervating the levator has been postulated². The origin of double elevator palsy has been believed to be supranuclear. Unilateral upgaze palsy has been seen in patients with documented supranuclear pathology⁷ either ipsilateral to the palsy or contralateral to it⁸.

Marcus Gunn phenomenon has been reported to occur in 2% to 13% of patients with congenital ptosis^{4,9,10}. We found an incidence of 11% in our study. All our cases were unilateral although bilateral cases have been reported.

It has been stated by Beard that Marcus Gunn syndrome is associated with a superior rectus weakness in approximately 75% cases⁵. Doucet and Crawford³ reported a 24 % incidence of superior rectus palsy. Prat et al⁴ showed a 25 % incidence of double elevator palsy and 23 % incidence of superior rectus palsy in their series. We have noticed a 50 % incidence of double elevator palsy in our patients.

Classical management of such cases with combined pathology has been, strabismus surgery followed by ptosis surgery. Amblyopia if present should be vigorously treated. In our series we were able to follow this rule in one case while in two cases we were unable to perform strabismus surgery because the patients were unwilling to undergo multiple procedures. We achieved reasonable cosmetic results, which were acceptable to the patients. One case was lost to follow up and did not undergo any surgical procedure.

Controversy exists over the optimal management of double elevator palsy. Successful alignment has been achieved following full vertical tendon width transpositions of the horizontal recti (Knapp procedure¹¹), partial tendon vertical transposition of the horizontal recti, conventional vertical and oblique surgery¹². Knapp procedure has become more popular

over the years. Thirteen to 73% of patients with DE palsy may develop secondary contracture of the inferior rectus in the paretic eye. Restriction is best detected by forced duction testing. If restriction is present it must be relieved by recession of the inferior rectus in order for the Knapp procedure to be successful.

Management of jaw winking ptosis requires assessment of both severity of jaw winking and magnitude of ptosis. Levator function must be measured with the mouth and jaw closed⁴. If the jaw winking is of minimal cosmetic significance, it can be ignored in the treatment of ptosis. Doucet & Crawford³ reported that jaw winking of 2 mm or more was considered cosmetically significant by patients, their parents, and their physician. It can be treated by levator resection if the levator function is good and jaw wink of minimal cosmetic significance. Beard⁵ has mentioned that undercorrection is common in such patients following levator resection alone, especially when the jaw wink is associated with superior rectus weakness. Moreover, jaw winking is more noticeable after levator resection due to higher postoperative lid level^{5,4}. We did not have any patients requiring levator resection in our series.

When the jaw winking is moderate to severe or is considered significant by the patient then levator excision with bilateral or unilateral frontalis suspension is preferred for the treatment of ptosis^{3,4,5,6,11,13}. Several surgical techniques have been suggested for the obliteration of levator function. Levator excision has been the most common technique used by many surgeons.^{3,5,6,9,10}. Attempted division of levator aponeurosis from all of its attachments below Whitnall's ligament is frequently incomplete. Even after complete removal of the aponeurosis, it is possible for fibrous connections between the levator muscle and eyelid to reform. Therefore the effect of levator excision on jaw winking is often incomplete⁵. Bilateral fascia lata sling with unilateral excision of the levator muscle has been the most commonly performed procedure^{3,4,5,6}. We performed unilateral autogenous fascia lata sling with excision of levator muscle in all our cases, with satisfactory results. The sample size was limited in the study because of the rarity of the disease.

CONCLUSION

In summary, patients undergoing ptosis surgery for correction of jaw winking ptosis should be thoroughly evaluated for the presence of double elevator palsy

(50% incidence). This is very helpful in achieving the best cosmetic outcome.

REFERENCES

1. Gunn RM. Congenital ptosis with peculiar associated movements of the affected lid. *Trans Ophthalmol Soc UK* 1883;3:283-7.
2. Miller NR, Walsh and Hoyt's Clinical Neuro-Ophthalmology, 4th ed. Vol. 2. Baltimore: Williams and Wilkins, 1985;949-51.
3. Doucet TW, Crawford JS. The quantification, natural course, and surgical results in 57 eyes with Marcus-Gunn (jaw-winking) syndrome. *Am J Ophthalmol* 1981;92:702-7.
4. Pratt SG, Beyer CK and Johnson CC. The Marcus Gunn phenomenon. A review of 71 cases. *Ophthalmology* 1984; 91(1):27-30.
5. Beard C. *Ptosis*, 3rd ed. St. Louis: CV Mosby, 1981; 113-5.
6. Khwarg SI, Tarbet KJ, Dortzbach RK, Lucarelli MJ. Management of moderate to severe Marcus-Gunn jaw winking ptosis. *Ophthalmology* 1999; 106(6): 1191-96.
7. Lessell S. Supranuclear paralysis of monocular elevation. *Neurology* 1975; 25:1134-1143.
8. Jampel RS, Fells P. Monocular elevation paresis caused by a central nervous system lesion. *Arch Ophthalmol* 1968;80:45-57
9. Spaeth EB. The Marcus Gunn phenomenon; discussion, presentation of four instances and consideration of its surgical correction. *Am J Ophthalmol* 1947; 30:143-58.
10. Iliff CE. The optimum time for surgery in Marcus Gunn phenomenon. *Trans Am Acad Ophthalmol Otolaryngol* 1970; 74:1005-10.
11. Knapp P. The surgical treatment of double elevator paralysis. *Trans Am Ophthalmol Soc* 1969;67:304-23.
12. Burke JP, Ruben JB, Scott WE. Vertical transposition of the horizontal recti (Knapp procedure) for the treatment of double elevator palsy: effectiveness and long term stability. *Br J Ophthalmol* 1992;76:734-737.
13. Bullock JD. Marcus jaw winking ptosis: classification and surgical management. *J Pediatr Ophthalmol Strabismus* 1980; 17(6):375-9.