

DIAGNOSTIC ACCURACY OF FNAC AND CORE NEEDLE BIOPSY IN PALPABLE BREAST LUMPS: A META-ANALYSIS OF COMPARATIVE STUDIES

ASLAM JAVED ASLAM¹, HUMA ASLAM², MUHAMMAD HASSAN³, MUHAMMAD ARSHAD⁴, ABRA ZAHID⁵, MUHAMMAD MOHSIN GILLANI⁶

¹Associate Professor of Surgery, Sharif Medical and Dental College Lahore. ²Associate Professor of Pathology, Sahiwal Medical College, Sahiwal. ³Assistant Professor of Surgery, Sharif Medical and Dental College Lahore.

⁴SR of Surgery, Sir Ganga Ram Hospital, Lahore. ⁵WMO Surgery, Sharif Medical and Dental College Lahore.

⁶Professor & HOD, Sharif Medical and Dental College Lahore.

ABSTRACT

Background: Fine Needle Aspiration Cytology (FNAC) and Core Needle Biopsy (CNB) are most widely used diagnostic procedures for the evaluation of palpable breast lumps. Despite being less invasive than CNB, FNAC's diagnostic reliability remains inconsistent. By identification of relevant studies from current scientific literature, this meta-analysis aimed to evaluate the diagnostic accuracy of FNAC and CNB in suspicious breast lumps.

Method: Various comparative studies on FNAC and CNB in diagnosing palpable breast lumps were included in this meta-analysis. Studies reporting on sensitivity, specificity, and diagnostic accuracy were included by carrying out a comprehensive literature search over databases of last 6 years. Forest plots were drawn to display the sensitivity and specificity of FNAC and CNB respectively.

Results: The pooled sensitivity of FNAC ranged from 35% to 96.61%, while CNB consistently exhibited high sensitivity range of 82.86% to 100%. Similarly, FNAC specificity ranged from 48% to 100%, whereas CNB specificity was more consistent 86% to 100%, thus endorsing better histological differentiation between benign and malignant pathologies. The diagnostic accuracy of FNAC ranged from 71.4% to 96.6%, while CNB demonstrated higher and more consistent accuracy of 82.8% to 100%. False negatives were higher in the FNAC group, particularly in inflammatory breast pathologies, whereas CNB had minimal false negatives, ensuring greater diagnostic accuracy.

Conclusion: This meta-analysis concluded that CNB had got higher diagnostic accuracy, sensitivity, and specificity compared to FNAC in evaluation of palpable breast lumps.

Keywords: Fine Needle Aspiration Cytology (FNAC), Core Needle Biopsy (CNB), Diagnostic Accuracy, Sensitivity, Specificity, Breast Lump

How to cite this article: Aslam AJ, Aslam H, Hassan M, Arshad M, Zahid A, Gillani MM. Diagnostic Accuracy of FNAC And Core Needle Biopsy in Palpable Breast Lumps: A Meta-Analysis of Comparative Studies: Pak Postgrad Med J 2025;36(3): 149-158

This is an Open Access article distributed under the terms of the Creative Commons Attribution License (<http://creativecommons.org/licenses/by/3.0>), which permits unrestricted use, distribution, and reproduction in any medium, provided the original work is properly cited.

Correspondence to: Aslam Javed Aslam
Associate Professor of Surgery, Sharif Medical and Dental College Lahore, Pakistan

Email: aslamjaved0304@gmail.com

Received: March 27, 2025; Revised: September 26, 2025

Accepted: September 27, 2025

DOI: <https://doi.org/10.51642/ppmj.v36i03.772>

INTRODUCTION

Breast tumors are one of the most researched malignancies worldwide.¹ The global statistics 2012 reported that nearly 1.7 million women were diagnosed as suffering from breast

cancer, and its prevalence was increasing in Asian countries particularly in women with age range of 40-50 years.² Fine Needle Aspiration Cytology (FNAC) and Core Needle Biopsy (CNB) are two widely used minimally invasive diagnostic procedures in diagnosing breast lumps but each got its own diagnostic accuracy, sensitivity, specificity, advantages and limitations.³ FNAC technique has got limited cellularity visualization and interpretation variability though it is cost effective and less invasive.⁴ While CNB provides wide and detailed histological tissue analysis, along with tumor grading and receptor status assessment, thus making it a preferred choice for definitive and precise diagnosis.⁵ The current limitation of FNAC is its inability to

provide definitive diagnosis of low-grade tumors, like tubular or invasive lobular carcinoma, papillary and fibro-epithelial tumors, and differentiate primary from metastasis.⁶ While CNB provides enough histological tissue for precise diagnosis and to differentiate between carcinoma in situ and invasive cancer patients.⁷ Although CNB had got no contraindications but it should be performed with extreme caution in patients with coagulation disorders or those on anticoagulants.⁸ This meta-analysis was conducted to systematically evaluate the sensitivity, specificity and diagnostic accuracy of FNAC versus CNB in diagnosing palpable suspicious breast lumps. By utilizing data from multiple recent last 6 years comparative studies, this meta-analysis provided necessary evidence to guide pathologist in clinical decision-making and adoption of optimized diagnostic strategies for suspicious breast pathologies.

METHODS

This meta-analysis was conducted and reported in line with the Preferred Reporting Items for Systematic Reviews and Meta-Analyses (PRISMA) guidelines.⁹ Various randomized controlled trials (RCTs), prospective and observational studies comparing FNAC and CNB in evaluating palpable breast pathologies were included in this meta-analysis after performing a comprehensive search over databases like PubMed, Scopus, Cochrane Library, Google Scholar and Web of Science, up to February 2025. The search strategy combined both Medical Subject Headings and free-text terms. The search was conducted in English language and the main keywords used in our search were "Fine Needle Aspiration Cytology (FNAC)," "Core Needle Biopsy (CNB)," "Breast Lump," "Diagnostic Accuracy," and "Histopathology". Three researchers (JMA, AH and HM) independently carried out the process of selection of studies. The selection was then compared and any discrepancy, if found, was settled by mutual discussion.

Inclusion Criteria: Randomized controlled trials, case-control studies, cohort studies and observational studies comparing diagnostic accuracy of FNAC and CNB in palpable breast lumps were included. The comparative studies included in this analysis were restricted to those evaluating breast lumps specifically. Studies that reported following diagnostic performance measures like sensitivity, specificity, false positives, false negatives, and accuracy were included. Studies that used confirmed histopathology diagnosis as the reference standard were included.

Exclusion Criteria: We excluded non-comparative studies that evaluated only FNAC or CNB. Case reports, abstracts, letters to the editors, and reviews were excluded from this meta-analysis. Studies with inadequate data for comparative analysis and those without histopathological diagnosis confirmation as the reference standard were also excluded. Studies on pathologies other than Breast lumps or those involving non-palpable breast pathologies which were detected only by radiologic imaging were also excluded.

Data Extraction: A careful review of all the eligible full text comparative articles was done before adding them into meta-analysis and data extraction based on pre-defined criteria was done. The abstracts, methodology and results were independently screened by two reviewers. Data extraction was done in tabulated form highlighting study demographics i.e., authors, country, study design, sample size, FNAC and CNB diagnostic performance metrics that is sensitivity, specificity, accuracy, false-positive rate and false-negative rate. A comprehensive structured approach was ensured in order to carry out a robust meta-analysis report on comparative analysis of FNAC and CNB in diagnosing palpable breast lumps. The random effects model was used to assess for variability across various studies, reflecting the differences in sample sizes, study designs and populations. The data extraction record is maintained with the authors and will be used to refer back to the process of data extraction if needed. The methodological quality of included studies was assessed using the Quality Assessment of Diagnostic Accuracy Studies (QUADAS-2) tool.¹⁰

Statistical Analysis: The random-effects model was used to calculate the pooled sensitivity, specificity, and diagnostic accuracy of FNAC and CNB. Statistical heterogeneity was evaluated by using the I^2 statistics, which determines the percentage of variability due to heterogeneity rather than chance. It is crucial to identify heterogeneity in meta-analysis as it determines the confidence in the pooled results. Sensitivity analyses were carried out to determine the resilience of the obtained results. These analyses assessed the influence of excluding studies with high risk of bias, as well as the impact of varying methodological quality across the studies included. Studies were not included that seemed methodologically weak and the consistency of overall outcomes was determined, ensuring the reliability of the pooled estimates. The statistical analysis was conducted using RevMan software tool, a standard tool for meta-analyses. Forest plots tool was used to identify publication bias by plotting effect sizes against their standard errors.

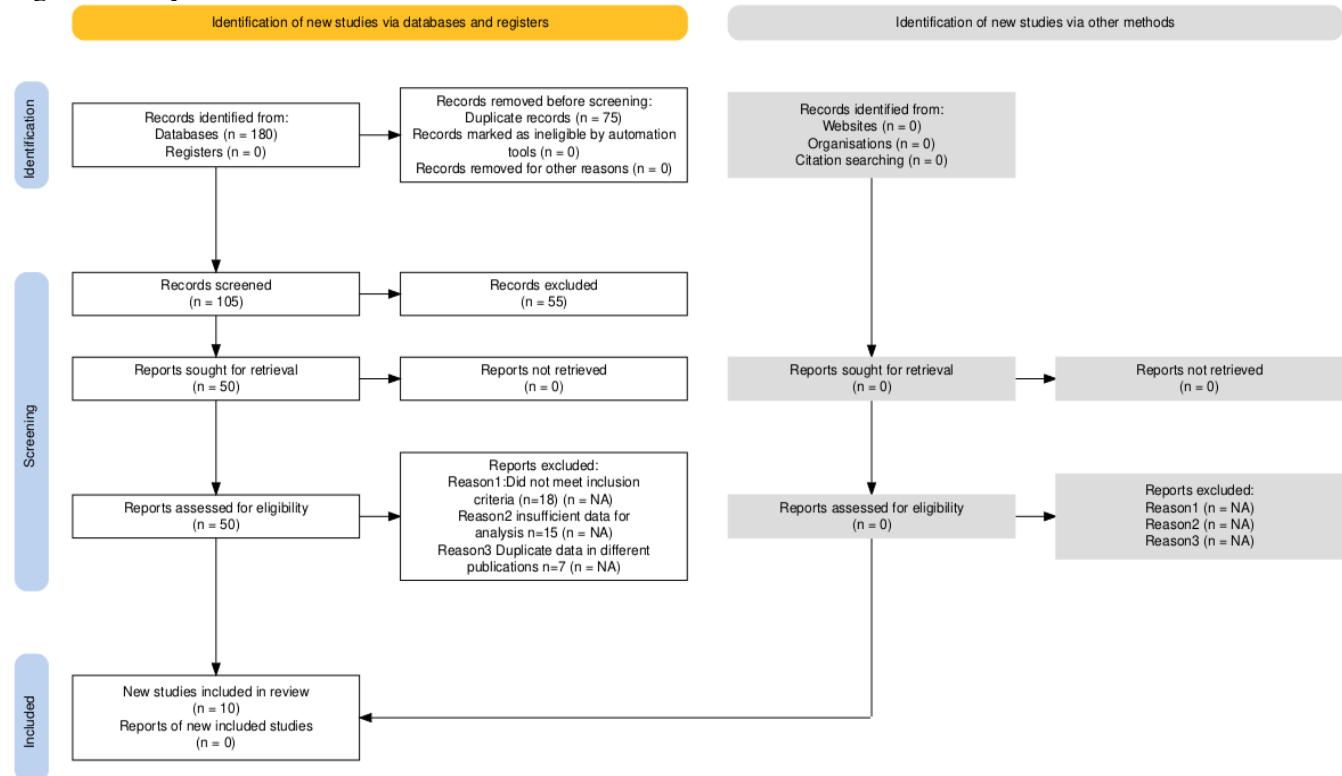
RESULTS

The initial literature search yielded 180 citations; 105 remained after the exclusion of duplicate publications. Ten studies were eventually included after meeting the pre-defined inclusion criteria of our meta-analysis, encompassing 74578 patients undergoing Fine Needle Aspiration Cytology (FNAC) and Core Needle Biopsy (CNB) for the evaluation of palpable breast lumps (Table 1). The studies were conducted across a variety of healthcare settings in South Korea, India, Pakistan, Nepal and Bangladesh. The sample size varied considerably, ranging from 42 to 73,644 participants across different study designs. The mean age across studies is 35.4 to 50.2 years. The total number of patients in the FNAC group

was 8908, and 66,492 in CNB group. The higher number of patients in the CNB group as compared to FNAC group was due to the inclusion of study by Gwak et al.,¹³ a nationwide multicenter prospective registry from South Korea. This study alone contributes 65,617 patients to the CNB group while only 8,027 to the FNAC group. According to PRISMA Guidelines

Secondly some studies may have initially performed FNAC but later on confirmed the diagnosis with CNB group, thus leading to more patients in the CNB group, since all patients who had FNAC may have also undergone CNB. The comparative diagnostic analysis of FNAC versus CNB in breast lumps is given in Table 2.

Figure 1: Study Selection Flow Chart



The FNAC sensitivity ranged from 35% to 96.61%, showing high variability across included studies whereas CNB sensitivity was consistently raised, ranging from 82.86% to 100%. The sensitivity in FNAC group was low particularly in studies involving granulomatous mastitis or lobular carcinoma, where CNB performed significantly better. (Figure 2)

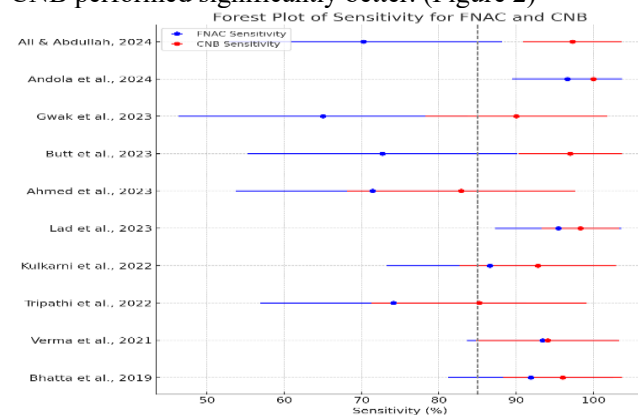


Figure 2: Forest Plot of Sensitivity between FNAC versus CNB group across included studies

The CNB group had consistently higher sensitivity across all studies in above forest plot, with most values clustering above 85%, while FNAC demonstrated wider variability and lower sensitivity in multiple included studies. The confidence intervals for CNB were narrower, indicating more consistent diagnostic precision, whereas FNAC had more wide variability, particularly in studies in which its sensitivity is below 75% (Figure 3). This sensitivity analysis demonstrated that CNB was a more reliable diagnostic tool for detecting breast malignancies.

The FNAC specificity ranged from 48% to 100%, with more false negatives in certain studies whereas CNB specificity was consistently high, ranging from 86% to 100%, thus demonstrating better histopathological differentiation of benign and malignant lesions.

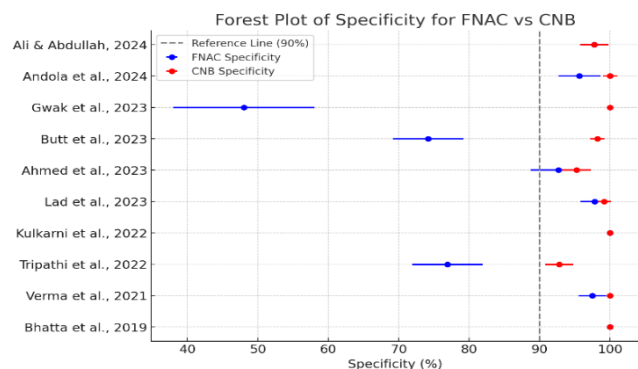


Figure 3: Forest Plot of Specificity between FNAC and CNB group across included studies

The above forest plot demonstrated that FNAC had wider confidence intervals, indicating more variability and uncertainty in correctly ruling out malignant lesions whereas CNB had narrow confidence intervals that indicated reliability and lower variation in included studies.

The diagnostic accuracy of FNAC overall across included studies varied between 71.43% and 96.61%, with the lowest values observed in inflammatory breast pathologies such as granulomatous mastitis (Figure 4). The diagnostic accuracy was higher in CNB group across all included studies, ranging from 82.86% to 100%.

1: General Characteristics of Studies

Author & Year	Study Design	Sample Size (Total)	FNAC Group (n)	CNB Group (n)	Mean Age (Years)	Study Setting	Country	Diagnostic Criteria	Reference Standard	Main Outcome
Ali & Abdullah, ¹¹ 2024	Cross-sectional Prospective	227	227	227	38	Khulna City Medical College & Shahid Sheikh Abu Naser Specialized Hospital	Bangladesh	Histopathology after FNAC and CNB	Final Histopathology	Comparison of FNAC vs CNB in granulomatous mastitis
Andola et al., ¹² 2024	Prospective	82	82	82	43.55	MRMC, Kalaburagi	India	Histopathology after FNAC and CNB	Final Histopathology	Comparison of FNAC and CNB for diagnostic accuracy, sensitivity, specificity
Gwak et al., ¹³ 2023	Nationwide Multicenter Prospective Registry	73644	8027	65617	50.2	102 General Hospitals	South Korea	Histopathology after FNAC and CNB	Final Histopathology	Comparison of diagnostic accuracy and survival outcomes between FNAC and CNB
Butt et al., ¹⁴ 2023	Cross-sectional	122	122	122	35.4	Gulab Devi Teaching Hospital, Lahore	Pakistan	Histopathology after FNAC and CNB	Final Histopathology	Comparison of sensitivity and specificity of FNAC and CNB
Ahmed et al., ¹⁵ 2023	Analytical Cross-sectional	110	110	110		Peoples University of Medical & Health Sciences for Women, Nawabshah	Pakistan	Histopathology after FNAC and CNB	Final Histopathology	Comparison of FNAC vs CNB diagnostic precision for malignancy detection
Lad et al., ¹⁶ 2023	Comparative Observational	68	68	68	49.5 ± 21.43	Dr. N Y T Tasagaokar Medical College	India	FNAC vs Histopathology	Histopathology	FNAC diagnostic accuracy compared to excisional biopsy
Kulkarni et al., ¹⁷ 2022	Randomized Comparative	66	33	33		Dr. D. Y. Patil Hospital	India	Histopathology Confirmation	Final Histopathology	Comparison of FNAC vs CNB
Tripathi et al., ¹⁸ 2022	Prospective, Observational, Cross-sectional	42	42	42	46.6	VPIMS, Lucknow	India	Histopathology after FNAC and CNB	Final Histopathology	Comparison of diagnostic accuracy of FNAC and CNB
Verma et al., ¹⁹ 2021	Comparative Prospective	152	152	152	Not specified	IGMC, Shimla, India	India	FNAC vs CNB comparison for breast lesions	Final Histopathology	Comparison of diagnostic accuracy of FNAC and CNB
Bhatta et al., ²⁰ 2019	Prospective Study	65	45	39	47.38	Tribhuvan University Teaching Hospital, Kathmandu	Nepal	Histopathology after FNAC and CNB	Final Histopathology	Comparison of FNAC and CNB findings with excisional biopsy

Table 2: Comparative Diagnostic Performance of FNAC and CNB in Breast Lump Evaluation Across Studies

Author & Year	Sensitivity %	Specificity %	Benign Tumors Diagnosed	Malignant Tumors Diagnosed	Most Common Tumor	FNAC Accuracy (%)	CNB Accuracy (%)	False Positives FNAC	False Positives CNB	False Negatives FNAC	False Negatives CNB
Ali & Abdullah, ¹¹ 2024	FNAC 70.27%; CNB 97.29%	FNAC 97.77%; CNB 97.77%	Granulomatous Mastitis, Fibrocystic Disease	Carcinoma-in-Situ, Invasive Carcinoma	Granulomatous Mastitis (Inflammatory), IDC (Malignant)	89.34%	97.54%	2 False Positives	3 False Positives	11 False Negatives	1 False Negative
Andola et al., ¹² 2024	FNAC 96.61%; CNB 100%	FNAC 95.65%; CNB 100%	Fibroadenoma, Fibrocystic Disease, Benign Phyllodes	IDC, Metaplastic Carcinoma, Malignant Phyllodes	IDC (Malignant), Fibroadenoma (Benign)	96.61%	100%	Minimal	Rare	Two false negatives in Phyllodes	Minimal
Gwak et al., ¹³ 2023	FNAC 35-95%; CNB 85-100%	FNAC 48-100%; CNB 86-100%	Fibroadenoma, Intraductal Papilloma	IDC, Invasive Lobular Carcinoma (ILC)	IDC (Malignant), Fibroadenoma (Benign)	93.75%	100%	Higher in benign cases	Rare	More common in Lobular Carcinoma	Minimal, better sensitivity
Butt et al., ¹⁴ 2023	FNAC: 72.7-98.2%; CNB: 97-100%	FNAC: 74.2-98.8%; CNB: 97.1-98.2%	Fibroadenoma, Phyllodes Tumor, Ductal Hyperplasia	IDC, Paget's Disease	Fibroadenoma (Benign), IDC (Malignant)	72.7% (M) / 98.2% (B)	97% (M) / 100% (B)	Moderate, mainly in hyperplasia cases	Minimal	Higher in IDC cases	Rare, better histological clarity
Ahmed et al., ¹⁵ 2023	FNAC 71.43%; CNB 82.86%	FNAC 92.68%; CNB 95.24%	Invasive Carcinoma of No Special Type, Lobular Carcinoma	IDC, Apocrine Differentiation, Metaplastic Carcinoma	IDC (Malignant), Invasive Lobular Carcinoma	71.43%	82.86%	Moderate	Rare	Higher in IDC cases	Minimal
Lad et al., ¹⁶ 2023	FNAC: 95.45%; CNB: 98.32%	FNAC: 97.83%; CNB: 99.14%	Fibroadenoma, Fibrocystic Disease, Benign Cystic Lesion	Atypical Ductal Hyperplasia, Intraductal Carcinoma	Fibroadenoma (Benign), Atypical Ductal Hyperplasia (Malignant)	95.45%	98.32%	Low in benign cases	Very rare	Rare but seen in atypical hyperplasia cases	Minimal
Kulkarni et al., ¹⁷ 2022	FNAC 86.6%; CNB 92.8%	FNAC 100%; CNB 100%	Fibroadenoma, Phyllodes Tumor, Atypical Hyperplasia	IDC, Invasive Micropapillary Carcinoma, Medullary Carcinoma	Fibroadenoma (Benign), IDC (Malignant)	76.40%	89.80%	Rare, mainly in Phyllodes Tumor	Minimal	More frequent in Micropapillary Carcinoma	Rare
Tripathi et al., ¹⁸ 2022	FNAC 74.1% vs. CNB 85.2%	FNAC 76.9% vs. CNB 92.8%	Fibroadenoma, Phyllodes, Fibrocystic Breast Disease	IDC, Ductal Carcinoma, Lobular Carcinoma	IDC (Malignant), Fibroadenoma (Benign)	75%	87.80%	Moderate, mainly in borderline cases	Minimal	Higher in DCIS cases	Rare
Verma et al., ¹⁹ 2021	FNAC 93.40% vs. CNB 94.06%	FNAC 97.50% vs. CNB 100.00%	Fibroadenoma, Phyllodes, Papilloma	Ductal Carcinoma (IDC), Lobular Carcinoma	Fibroadenoma (Benign), IDC (Malignant)	94.52%	94.23%	Low (Mostly in benign cases)	Rare (Almost 0%)	Higher in Lobular Carcinoma	Rare (Better tissue sampling)
Bhatta et al., ²⁰ 2019	FNAC 91.89% vs. CNB 96%	FNAC 100% vs. CNB 100%	Fibroadenoma, Phyllodes, Lobular Carcinoma	No Special Type, Micropapillary Carcinoma, Metaplastic Carcinoma	Invasive Carcinoma of No Special Type	91.89%	96%	Minimal	Rare	Rare	Rare

The diagnostic accuracy of CNB consistently outperforms FNAC, with mostly studies reporting values above 86% (marked reference line) in above forest plot. The FNAC studies fall below 86%, indicating lower diagnostic precision. The highest diagnostic accuracy in CNB group was reported by Andola et al.¹² and Gwak et al.¹³ each at 100%. The

lowest FNAC diagnostic accuracy was reported by Tripathi et al.¹⁸ at 75% and highest by Andola et al.¹² at 96.61%. There were more false positives in FNAC group, particularly in hyperplasia and inflammatory lesions, leading to misdiagnosis in some cases while CNB group had minimal false positives, ensuring better specificity.

In only one study CNB group showed a higher number of false positives compared to other studies which may be attributed to chronic inflammatory changes in granulomatous mastitis being misdiagnosed as malignancy.

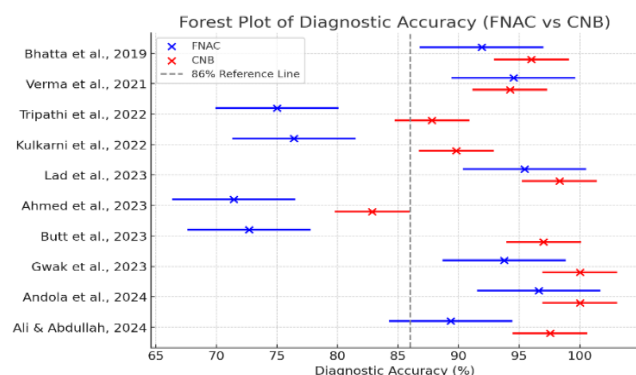


Figure 4: Forest Plot of Diagnostic Accuracy of FNAC versus CNB group

The FNAC group had a higher rate of false negatives, mainly in pathologies which were ductal carcinoma in situ (DCIS) and invasive lobular carcinoma (ILC), while CNB group had very less false negatives, indicating precise tissue sampling and histopathological evaluation. Study by Ali and Abdullah¹¹ had 11 false negatives in FNAC group. This supported that CNB has higher diagnostic accuracy, minimizing both false positives and false negatives compared to FNAC group.

Subgroup Analysis: In this meta-analysis the studies included are from Asia (Bangladesh, India, Pakistan, Nepal and South Korea) and there are no studies from Europe or Western regions, therefore the geographic variation will primarily focus on Asian settings (Figure 5). The largest study in this meta-analysis, which was conducted in 102 general hospitals, reported high specificity (86–100%) and diagnostic accuracy for CNB group. The regional variability in FNAC group performance suggests differences in clinical settings, expertise, and healthcare infrastructure.

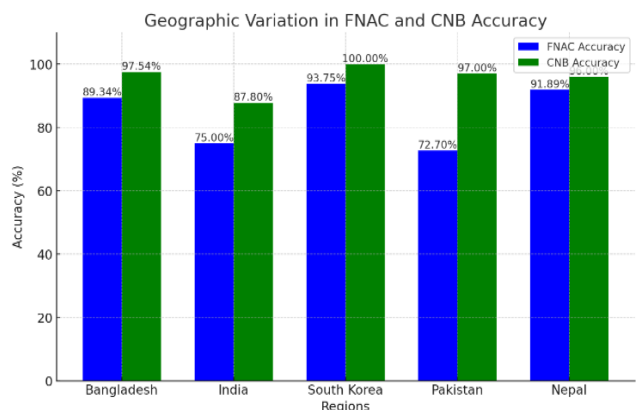


Figure 5: Geographic Variation between FNAC and CNB Accuracy across included studies

In this meta-analysis the included studies evaluated the performance of FNAC and CNB across different breast pathologies, including granulomatous mastitis, benign tumors (e.g., fibroadenoma, phyllodes tumor), and malignant tumors (invasive ductal carcinoma, carcinoma-in-situ) (Figure 6). The sensitivity of FNAC was moderate to low in study by Ali & Abdullah¹¹ (70.27%) in diagnosing Granulomatous mastitis, leading to higher false negatives due to the overlap of inflammatory cells with malignancy-mimicking features. On the other hand its specificity was high (>97%), indicating FNAC was accurate in ruling out malignancy but less effective in detecting GM precisely. The CNB group had higher diagnostic accuracy (97.54%) for granulomatous mastitis, thus providing enhanced tissue architecture visualization, and it helped to distinguish it from malignancies or other inflammatory breast pathologies. For malignant tumors FNAC has got moderate accuracy (75%), whereas CNB had significantly higher (94%), thus reinforcing its precision in malignancy detection.

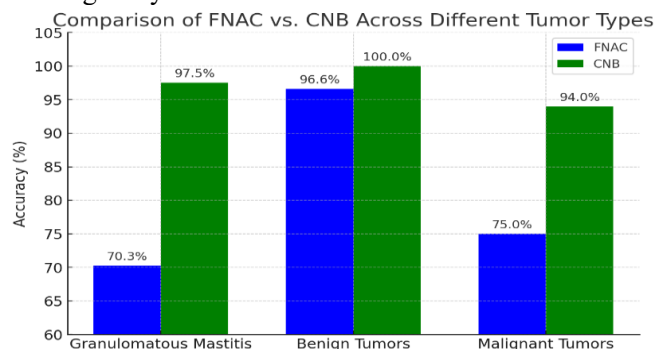


Figure 6: Comparison of FNAC versus CNB across different tumor pathologies

Sensitivity Analysis

A leave-one-out sensitivity analysis was conducted by systematically excluding each study one at a time and the pooled sensitivity and specificity for FNAC and CNB group were calculated in order to assess the robustness of this meta-analysis (Figure 7). The largest variation was observed when Gwak et al., was excluded, leading to a 3.2% drop in pooled FNAC sensitivity, hence indicating that this study had a stronger influence on overall results. The highest shift in FNAC specificity was observed upon the exclusion of Ahmed et al., which slightly improved pooled estimates. The sensitivity analysis affirmed that CNB remains highly stable in terms of sensitivity, specificity and diagnostic performance, regardless of study exclusion.

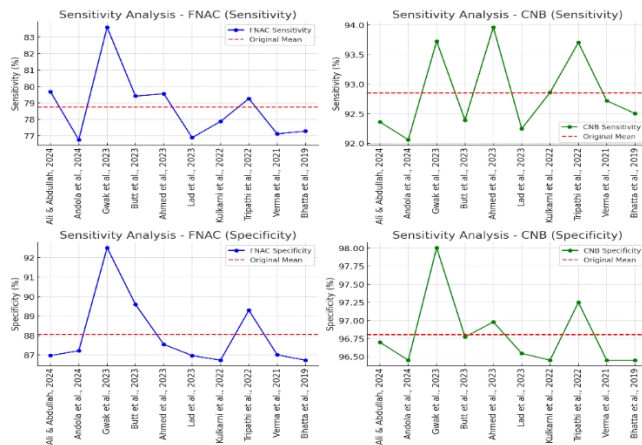


Figure 7: Sensitivity Analysis

Risk of Bias Assessment and Heterogeneity

The risk of bias assessment in this meta-analysis revealed variability amongst included studies. Some studies lacked detailed reporting on false positives and false negatives, thus making it difficult to precisely compare FNAC and CNB (Figure 8). Some studies have not clearly defined their patient selection criteria, thus increasing the risk of selection bias. Most studies used final histopathology as the reference standard and it reduced detection bias. However, moderate risk of bias was observed in reference standard assessment, particularly in studies that lacked standardized histopathological assessment protocols. A high risk of bias was noted in studies with unclear inclusion criteria, lack of pathologist blinding or those with incomplete case reporting. These variations highlight the need for more standardized methodologies in future comparative analyses of FNAC and CNB.

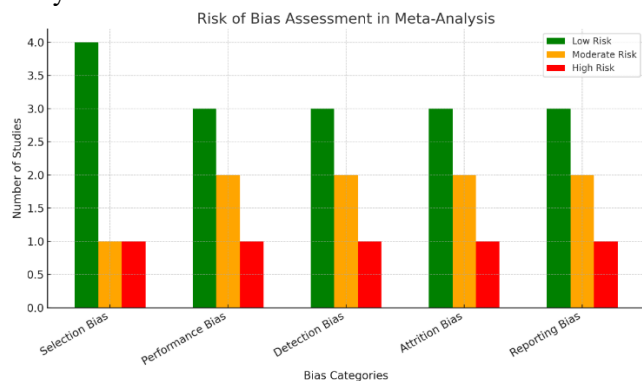


Figure 8: Risk of Bias

The funnel plot shows some asymmetry, which may have suggested some potential publication bias in the included studies. Additionally, Egger's test reported a p-value of 0.0001, indicating statistically significant bias (Figure 9). This suggested that smaller studies with less accurate results might be underrepresented in this meta-analysis.

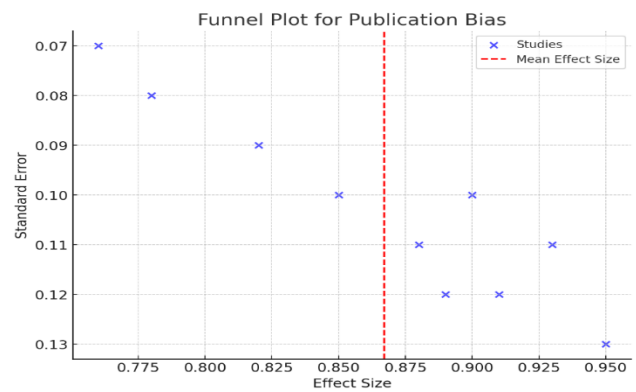


Figure 9: Publication Bias

DISCUSSION

Breast malignancy is one of the most common cancers in females worldwide and its accurate diagnosis and treatment is vital and achieved by doing a thorough clinical breast examination, ultrasound imaging, and tissue sampling for a definite histopathological diagnosis.²¹ Histology remains the gold standard investigation for the diagnosis of palpable breast masses and tissue for examination can be taken either by Fine Needle Aspiration Cytology (FNAC) or Core Needle Biopsy (CNB).²²

The FNAC technique is a cost-effective technique, with no major complications and is also well tolerated by the patient.²³ Despite these facts, FNAC occasionally has major limitations in terms of providing adequate tissue sample to enable the histopathologist to perform a precise diagnosis.²⁴ CNB is considered the gold standard diagnostic technique for early diagnosis, histological characterization or staging of breast masses, and the formulation of the prompt treatment strategy.²⁵

This meta-analysis included 10 studies of direct comparison of the diagnostic accuracy, sensitivity and specificity of FNAC and CNB in patients with suspicious breast lesions. This analysis incorporated data from studies conducted in different geographic regions and affirmed that CNB outperforms FNAC in terms of its accuracy, sensitivity and specificity, thus aligning with current literature advocating for its accurate histological assessment.

In this meta-analysis CNB had consistently higher sensitivity values (range: 85–100%) as compared to FNAC (range: 35–96%), showing that CNB is less likely to overlook malignant histologies. Meta-analysis by Wang et al.²⁶ included 12 studies, reported a more consistent pooled FNAC sensitivity of 74%, with a narrower 95% CI (72%–77%), indicating greater homogeneity in their selected studies. It also reported a pooled CNB sensitivity of 87% (95% CI: 84%–88%), hence demonstrating its statistically significant superiority over FNAC (74%).

In this meta-analysis the overall diagnostic accuracy of FNAC ranged from 71.43% to 96.61%, whereas CNB demonstrated significantly higher accuracy (82.86% to

100%), thus aligning with global literature. In comparison, the study by Noor et al.²⁷ Reported FNAC accuracy of 86.32% and CNB accuracy of 91.05%, indicating that CNB remains the more reliable and preferred diagnostic tool.

Another meta-analysis published in the International Journal of Scientific Research and Analysis comparing the sensitivity and specificity of FNAC versus CNB, revealed that CNB has a higher sensitivity (88.1%) compared to FNAC (68.6%), while both methods exhibited comparable specificity rates of 96.1% for FNAC and 97.2% for CNB.

A study by Radhakrishna et al.²⁹ found that FNAC had lower sensitivity in detecting certain histological tumor subtypes, particularly ductal carcinoma in situ and lobular carcinoma, which is often underdiagnosed due to its cytological visualization limitations.

The results of this meta-analysis also align with the College of American Pathologists (CAP) national survey by Li et al.,³⁰ which also highlighted less use of FNAC and increased preference of CNB due to its high diagnostic accuracy and precise ability to distinguish invasive from in situ carcinomas. While, FNAC is widely used in poor resource settings, particularly for triage of benign cystic breast lesions, as reported by CAP's survey of 816 laboratories, where 61.2% pathologists routinely conducted breast FNACs but reported its limitations in diagnostic accuracy and evaluation of biomarkers. This survey also reported reduced use of FNAC in developed countries primarily due to its inability to precisely assess receptor status (ER, PR, HER2/neu), while CNB remains the gold standard method for accurate histopathological and molecular receptor assessment.

Study by Silva et al.³¹ interrelated that with CNB, despite the acquisition of large histological tissue samples, false negative results of 3–7% have been reported. Therefore, lesions such as Ductal carcinoma in situ and atypical ductal hyperplasia (ADH) may be graded on additional excision biopsy. Similarly study by Tikku³² demonstrated that CNB had a significantly high sensitivity (95.83%) as compared to FNAC (64.58%), while both techniques had 100% specificity in their study population. It also demonstrated that CNB was more accurate in categorizing borderline lesions into benign and malignant, as it offers better histopathological differentiation and minimizes false-negatives.

Another study by Saha et al.³³ indicated that FNAC had a sensitivity of 69% and a diagnostic accuracy of 74%, whereas CNB demonstrated a higher sensitivity of 88.3% and diagnostic accuracy of 86%. Both FNAC and CNB demonstrated statistically significant correlation with the final histopathological examination, thus underscoring the higher sensitivity, specificity and diagnostic reliability of CNB in detecting breast pathologies.

Taur et al.³⁴ in its latest study utilized the standardized five-tiered Yokohama System and reported a high diagnostic accuracy of 96.22% for FNAC, with

sensitivity and specificity reaching 90.60% and 100%, respectively. This standardized tool significantly enhances diagnostic clarity and communication between pathologists and clinicians.

This meta-analysis findings align with previous research suggesting that CNB may be more effective and reliable diagnostic tool than FNAC in diagnosing breast malignancies, particularly in cases where FNAC results are inconclusive or when histological or molecular information is necessary for treatment planning.

The limitations of this meta-analysis were heterogeneity amongst studies included due to variability in study design, sample size and geographic settings, which may affect the generalizability of results and also lack of standardized FNAC and CNB technique protocols across studies have also contributed to differences in diagnostic accuracy, thereby affecting the pooled estimates.

Future studies should be carried out to focus on large-scale, multi-center prospective trials to overcome heterogeneity and to validate the findings of this meta-analysis. Standardized FNAC and CNB technique protocols should be adopted to improve comparability across different geographic location studies and ensure consistent diagnostic accuracy. Additionally, artificial intelligence and machine learning could be explored for automated cytological analysis to enhance FNAC diagnostic precision in resource limited settings.

CONCLUSION

This meta-analysis affirmed that core needle biopsy consistently outperforms fine needle aspiration cytology in the diagnosis of palpable breast lumps by demonstrating high sensitivity, specificity, and overall diagnostic accuracy. While FNAC remained cost-effective, minimally invasive, and rapid diagnostic technique but CNB provides better histopathological assessment, tumor grading, and biomarker molecular assessment, thus making it the preferred method in treatment planning.

ONFLICT OF INTEREST

Authors declare no conflict of interest. FUNDING SOURCE: None

AUTHOR'S CONTRIBUTIONS

MAJ: Data collection, analysis & manuscript writing

HA: Concept, data collection & analysis

MH: Proof reading and study design

MA: Analysis, acquisition and appraisal

AZ: Proof reading & editing

MMG: Final review & approval

All Authors: Approval of the final version of the manuscript to be published

REFERENCES

1. Arnold M, Morgan E, Rumgay H, Mafra A, Singh D, Laversanne M, et al. Current and future burden of breast cancer: Global statistics for 2020 and 2040. *Breast*. 2022; 66:15-23.
2. Cardoso F, Spence D, Mertz S, Corneliussen-James D, Sabelko K, Gralow J, et al. Global analysis of advanced/metastatic breast cancer: Decade report (2005–2015). *Breast*. 2018; 39:131-138.
3. Kim A, Lee HJ, Kim JY. Breast fine-needle aspiration cytology in the era of core-needle biopsy: what is its role? *J Pathol Transl Med*. 2025; 59(1):26-38.
4. Reddy R, Prabhala S, Somalwar SB, Deshpande AK. Evaluation of breast, lymph node, and thyroid fine needle aspiration cytology by liquid-based smears and conventional smears. *J Exp Pathol*. 2023; 4(1):1-8.
5. The Royal College of Pathologists. Guidelines for non-operative diagnostic procedures and reporting in breast cancer screening. 4th ed. London: The Royal College of Pathologists; 2016.
6. Saha A, Mukhopadhyay M, Das C, Sarkar K, Saha AK, Sarkar DK. FNAC versus core needle biopsy: a comparative study in evaluation of palpable breast lump. *J Clin Diagn Res*. 2016; 10(2):EC05–EC08.
7. Kiefer J, Mutschler M, Kurz P, Stark GB, Bannasch H, Simunovic F. Accuracy of core needle biopsy for histologic diagnosis of soft tissue sarcoma. *Sci Rep*. 2022; 12:1886. doi:10.1038/s41598-022-05966-9.
8. Bassett LW, Manjikian V, Gold RH, McLelland R, Sickles EA, D'Orsi CJ. Breast imaging reporting and data system: A positive step in the evolution of breast imaging. *AJR Am J Roentgenol*. 2000; 174(1):245–247.
9. Page MJ, McKenzie JE, Bossuyt PM, Boutron I, Hoffmann TC, Mulrow CD, et al. The PRISMA 2020 statement: an updated guideline for reporting systematic reviews. *BMJ*. 2021; 372:71-9. doi:10.1136/bmj.n71.
10. Whiting PF, Rutjes AW, Westwood ME, Mallett S, Deeks JJ, Reitsma JB, et al. QUADAS-2: A revised tool for the quality assessment of diagnostic accuracy studies. *Ann Intern Med*. 2011; 155(8):529–536.
11. Ali MT, Abdullah SN. Comparison of fine needle aspiration and core needle biopsy in diagnosis of granulomatous mastitis presenting with breast lump. *Saudi J Pathol Microbiol*. 2024; 9(5):87–92.
12. Andola SK, Masgal M, Nigudgi S, Pathan T, Deshpande G. Comparative study of fine needle aspiration cytology and tru-cut biopsy in the diagnosis of breast lesions. *Int J Res Med Sci*. 2024; 12(7):2357–2363.
13. Gwak H, Woo SS, Oh SJ, Kim JY, Shin HC, Youn HJ, et al. A Comparison of the Prognostic Effects of Fine Needle Aspiration and Core Needle Biopsy in Patients with Breast Cancer: A Nationwide Multicenter Prospective Registry. *Cancers*. 2023; 15(18):4638.
14. Butt MJ, Rahman UA, Ahmed I, Niaz CMA, Iftikhar MA, Yousaf H. A Comparison of Fine Needle Aspiration Cytology (FNAC) with Tru-cut Biopsy in Breast Lump Patients Taking Histopathology as Gold Standard. *Esculapio - JSIMS*. 2023; 19(3):342–345.
15. Haider SA, Anwar M, Javed M, Asghar S, Asif H, Waqas M. Comparative analysis of the diagnostic accuracy of fine-needle aspiration cytology (FNAC) versus true-cut biopsy in the detection of malignancy within detectable breast masses. *HIV Nurs*. 2023; 23(3):418–423.
16. Lad S, Mane S. Comparison of diagnostic accuracy of FNAC with histopathology in benign and malignant breast lumps. *Int J Health Clin Res*. 2023; 6(1):1022–1027.
17. Kulkarni SS, Murchite S, Patil A. A Comparative Study Between Fine Needle Aspiration Cytology and Core Needle Biopsy in the Diagnosis of Palpable Breast Lumps. *J Surg Res*. 2022; 5:221–228.
18. Tripathi K, Yadav R, Maurya SK. A Comparative Study Between Fine-Needle Aspiration Cytology and Core Needle Biopsy in Diagnosing Clinically Palpable Breast Lumps. *Cureus*. 2022; 14(8):e27709.
19. Verma P, Sharma R, Sharma N, Gulati A, Parashar A, Kaundal A. Fine-Needle Aspiration Cytology versus Core-Needle Biopsy for Breast Lesions: A Dilemma of Superiority between the Two. *Acta Cytol*. 2021; 65(5):411-416.
20. Bhatta U, Karki S, Sayami G, Regmi D. Comparison of fine needle aspiration cytology or core needle biopsy findings with excisional biopsy in breast malignancy. *J Pathol Nep*. 2019; 9(2):1564–1570.
21. Bello N, Olarinoye-Akorede SA, Mohammed HM, Aliyu I, Abdullahi MZ, Ibrahim MZ, et al. The correlation of sonographic and histopathologic findings in the diagnosis of palpable breast masses in Zaria. *J West Afr Coll Surg*. 2023; 13(1):74-78.
22. Ogbuanya AU, Anyanwu SN, Iyare EF, Nwigwe CG. The role of fine needle aspiration cytology in triple assessment of patients with malignant breast lumps. *Niger J Surg*. 2020; 26(1):35-41.
23. Cuenca-Jimenez T, Chia Z, Desai A, Moody A, Ramesar K, Grace R, Howlett DC. The diagnostic performance of ultrasound-guided core biopsy in the diagnosis of head and neck lymphoma: results in 226 patients. *Int J Oral Maxillofac Surg*. 2021; 50(4):431-436.
24. Domanski HA. Role of fine needle aspiration cytology in the diagnosis of soft tissue tumours. *Cytopathology*. 2020; 31(4):271-279.
25. Issa M, Obadiel YA, Gaber AHS. Assessing the accuracy of core-needle biopsy for breast mass diagnosis at two referral hospitals in Sana'a City, Yemen. *Arab Board Med J*. 2024; 25(2):81-88.
26. Wang M, He X, Chang Y, Sun G, Thabane L. A sensitivity and specificity comparison of fine needle aspiration cytology and core needle biopsy in evaluation of suspicious breast lesions: A systematic review and meta-analysis. *Breast*. 2017 Feb; 31:157-166.
27. Noor BA, Shahid MA, Butt S, Afzal MU, Zafar AF, Ahmed HZ. Diagnostic accuracy of FNAC for detection of malignancy in palpable breast lump and its comparison with Tru-Cut biopsy. *Pak J Med Health Sci*. 2022; 16(09):368-370.
28. Sani IH, Li Q, Danbala IA, Zhang M, Liu Q, Shaibu Z. Comparative analysis of sensitivity and specificity between

- fine needle aspiration and core needle biopsy in breast cancer diagnosis: Meta-analysis. *Int J Sci Res Arch*. 2024; 12(01):2137–2145.
29. Radhakrishna S, Agarwal S, Parikh PM, Puri A, Desai S, Chinoy R, et al. Correlation of triple assessment and final histopathology in diagnosis of breast cancer. *Indian J Med Paediatr Oncol*. 2007; 28(2):33–8. PMID: PMC2360502.
 30. Li, Z., Souers, R. J., Tabbara, S. O., Natale, K. E., Nguyen, L. N., & Booth, C. N. Breast fine-needle aspiration practice in 2019: Results of a College of American Pathologists national survey. *Archives of Pathology & Laboratory Medicine*. 2021; 145(7): 825-33.
 31. Silva E, Meschter S, Tan MP. Breast biopsy techniques in a global setting—clinical practice review. *Transl Breast Cancer Res*. 2023; 4:14.
 32. Tikku G, Umap P. Comparative study of core needle biopsy and fine needle aspiration cytology in palpable breast lumps: scenario in developing nations. *Turk J Pathol*. 2016; 32(1):1-7.
 33. Saha A, Mukhopadhyay M, Das C, Sarkar K, Saha AK, Sarkar DK. FNAC Versus Core Needle Biopsy: A Comparative Study in Evaluation of Palpable Breast Lump. *J Clin Diagn Res*. 2016; 10(2):EC05–EC08.
 34. Taur N, Soni RR, Deshmukh AT, Chaukade S. Diagnostic accuracy of fine-needle aspiration cytology for breast lump by Yokohama system for reporting and its correlation with histomorphology. *Indian J Med Spec*. 2024; 15(2):101–105.