

JUVENILE NASOPHARYNGEAL ANGIOFIBROMA: OUR EXPERIENCE AND LITERATURE REVIEW

ADEEL NIAZ, MUHAMMAD IQBAL, MUHAMMAD ILYAS, GHULAM DASTGIR KHAN,
RIAZ AHMAD, MUHAMMAD TARIQ

Department of ENT, Postgraduate Medical Institute/Ameer ud Din Medical College/ Lahore General Hospital, Lahore.

ABSTRACT

Background: Angiofibroma which is also known as Juvenile Nasopharyngeal Angiofibroma or JNA is considered to be a tumor which is benign in nature and composed of vascular network. It is commonly found in teen age males. Its site of origin is thought to be sphenopalatine foramen. True pathological mechanism of angiofibroma is still debatable. It has predictable natural history and growth pattern. This tumor most often involves nasopharynx, nasal cavity, paranasal sinuses, pterygopalatine fossa and infratemporal fossa. It can also involve orbit and can spread intracranially. Its very important to diagnose this tumor very early on the basis of clinical examination and imaging. As early tumor confined to nose and sinuses can be removed exclusively with endoscope. It is very helpful to do angiography before surgery to ascertain its blood supply and then embolization can be done to reduce intraoperative bleeding.

Objective: To describe our experience of Juvenile Nasopharyngeal Angiofibroma cases in ENT Unit-I of Lahore General Hospital.

Methods: Descriptive Study with retrospective analysis after approval from Institutional Review Board (IRB) of LGH/PGMI/AMC Lahore. We studied 20 patients who underwent surgery in our department from October 2019 to October 2020. We analyzed following factors: age, gender, symptoms, staging and mode of surgery and need for intraoperative blood transfusion, hospital stay, complications and recurrences.

Results: Range of patient's age was 12 to 25 years. Eight patients underwent surgery with endoscope. Mean blood loss was about 400 ml and mean operating time was 140 minutes. All the cases were embolized preoperatively.

Conclusion: Endoscopic surgery is a safe and effective method in early stage JNA patients. While patients with advance stage tumors should be managed with combined endoscopic and conventional open approaches.

Keywords: Angiofibroma, JNA, endoscopic sinus surgery, nasopharyngeal Angiofibroma.

How to cite this article: Niaz A, Iqbal M, Ilyas M, Khan GD, Ahmad R, Tariq M. Juvenile nasopharyngeal angiofibroma: our experience and literature review Pak Postgrad Med J 2020;32(1). 3-8

This is an Open Access article distributed under the terms of the Creative Commons Attribution License (<http://creativecommons.org/licenses/by/3.0>), which permits unrestricted use, distribution, and reproduction in any medium, provided the original work is properly cited.

DOI: <https://doi.org/10.51642/ppmj.v32i01.406>

Correspondence to: Adeel Niaz, Department of ENT, Postgraduate Medical Institute/Ameer ud Din Medical College/ Lahore General Hospital, Lahore, Pakistan.

Email: dradeelniaz@gmail.com

INTRODUCTION

This tumor was described in history as early as 5th century BC by Hippocrates. It was Friedberg who in 1940 gave this tumor name of Angiofibroma.¹ It is a tumor composed of vascular framework and it mostly affects teenage males. This tumor is pathologically

benign but locally aggressive and 'malignant' by location. Also it tends to recur frequently. Vessels which are in center of tumor are deficient in muscular elastic laminae and due to this reason these tend bleed massively.² The exact site of origin is still unclear with current opinion being the postero-superior margin of the sphenopalatine foramen or from contents of vidian canal. Most recent theory considers that it is a vascular malformation which results from first branchial arch artery incomplete involution or regression.³ Growth and extension of angiofibroma is determined radiologically by contrast enhanced computerized tomography (CT) scan. Because of JNA's tendency to

bleed profusely its biopsy is not carried out before definitive surgery. The condition is most commonly treated by surgical excision. Surgical approach is decided by its clinical and radiological staging. Patients who have intracranial extension of tumor and which are not fit for surgery are usually treated by Radiotherapy.

METHODS

We studied 20 patients of Angiofibroma which were treated in our department from October 2019 to October 2020. Variables analyzed were age, gender, symptoms, staging, surgical approach, intraoperative bleeding, hospital stay, complications and recurrence. Patients were staged with Fisch Classification with the help of clinical examination and imaging.

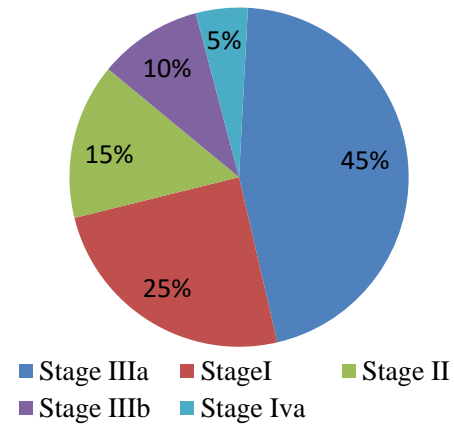
RESULTS

Mean age of patients was 16 years and range was 12 to 25 years. Gender was male in all patients. Epistaxis was most common clinical presentation along with nasal obstruction. According to Fisch classification 5 (25%) patients were in Fisch stage I, 3 (15%) Fisch stage II, 9 (45%) in stage IIIa, 2 (10%) in stage IIIb and 1 patient (5%) in stage Iva. We operated 8 patients in stage I, II with Transnasal Endoscopic approach while 12 patients which were above stage II were operated through combined endoscopic and open approaches like Midfacial Degloving and Caldwell Luc approach. Patients who were treated endoscopically their mean procedure (Operative) time was 122 mins while average blood loss calculated was 250 ml with no need for blood transfusion. All these patients were discharged the next day as there was no post operative nasal packing performed. These patients did not had any intra and post operative complications. Among patients which were operated through combined endoscopic and open approaches 4 patients required intra-operative blood transfusion due to significant hemorrhage. Average blood loss calculated is 600 ml. These patients were discharged after 72 hours after removing their nasal packs. In these patients 3 patients had post operative numbness of cheek due to damage to infraorbital nerve. One patient developed Oroantral fistula. No major intra orbital or intra cranial complication was noted in these patients. All patients underwent preoperative carotid angiography and embolization.

Stage wise distribution of JNA patients using Fisch staging system and represented in Pie Chart

DISCUSSION

Angiofibromas are vascular tumors which present in the nasal cavity and nasopharynx of teen age males.



JNA has a typical clinical pattern affecting teen age males. Rarely some cases are seen in females and older patients. Initial symptom is bleeding which may present as epistaxis or blood stained nasal discharge. Other symptoms are one sided nasal obstruction and aural blockage or fullness secondary to secretory otitis media. As tumor grows in size other symptoms at presentation are simple nasal discharge or blood stained discharge, headache, disturbance of smell, palatal swelling along with swelling of the cheek. When orbit is involved then there will be proptosis, decreased vision and epiphora. With involvement of pterygoids and infra temporal fossa there will be trismus^{4,5}. Clinical examination with anterior rhinoscopy and endoscopy reveals a rubbery, lobulated, smooth red or purple mass with increased vascularity. It may be arising from behind the middle turbinate which is pushed laterally. There will also be obstruction of posterior nasal cavity^{4,5}. This tumor grows under mucosa so it may give appearance as its origin from middle turbinate. When probing is performed it bleeds on touch. It may also show some pulsations during endoscopy. (Figures 1 and 2). There may be displacement of soft palate due to mass in nasopharynx.

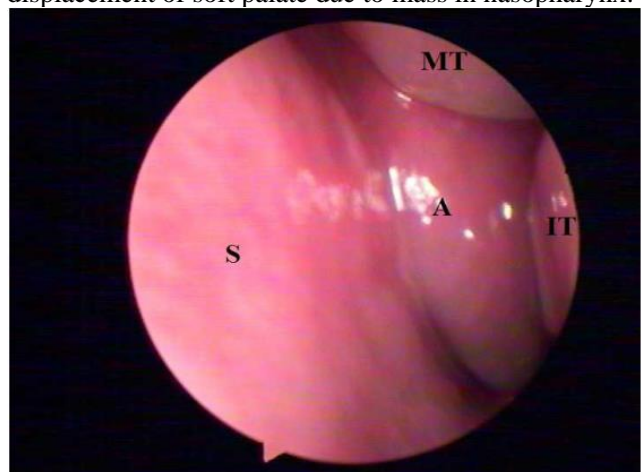


Fig.1: Endoscopic picture of left nasal cavity. A=Angiofibroma, IT=Inferior Turbinate, MT= Middle Turbinate, S= Septum

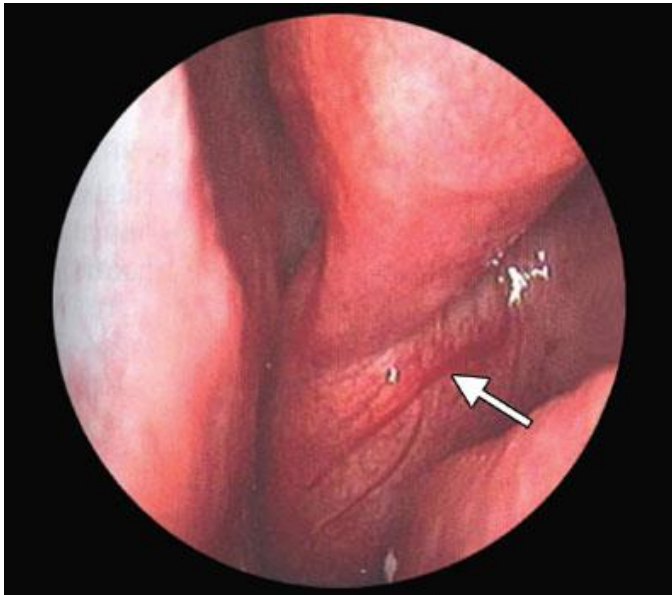


Fig.2. Endoscopic picture of JNA. Arrow pointing towards prominent blood vessels on surface of tumor

MICROSCOPY: Microscopic studies show that it consists of fibro-vascular stroma with numerous capillaries. Cells of this tumor are composed of endothelial cells, myofibroblasts with numerous nuclei and pleomorphic appearance, and smooth muscles which lack ability of vasoconstriction. Due to these characteristics angiofibromas tend to bleed profusely. Mitotic activity is not present^{10,11}.

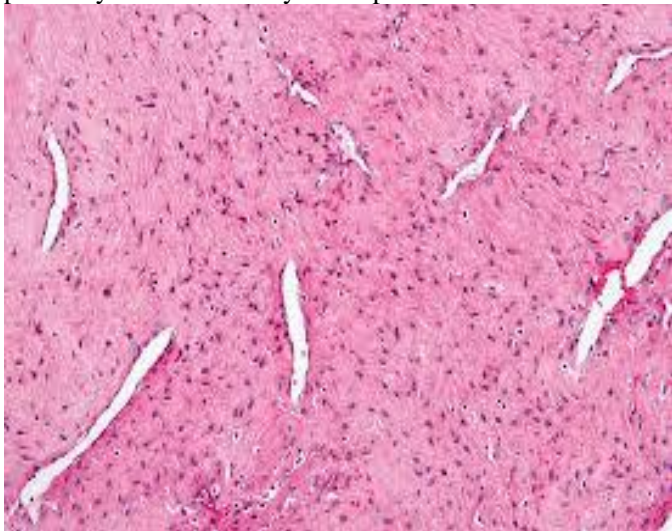


Fig. 3: Microscopic picture of JNA showing fibrovascularstroma with numerous capillaries

RADIOLOGY: Simple X-Rays have no role in diagnosis of Angiofibroma. CT scan is the best initial investigation. It shows heterodense, non-encapsulated soft tissue density mass centered on the sphenopalatine foramen. In majority of cases this tumor invades nasopharynx, pterygopalatine fossa and causes widening of sphenopalatine foramen and also causes bowing of the posterior wall of maxillary sinus which is also called

“Holman-Miller sign”. Angiofibromas tend to grow through least resistant pathways and cause bone destruction by remodeling and resorption. At advance stage it spreads to sphenoid, maxillary or ethmoid sinuses, infratemporal fossa, orbit and the skull base. On CT Scan contrast enhancement confirms the abundant vascularity^{12,13} (Figures 4 and 5).

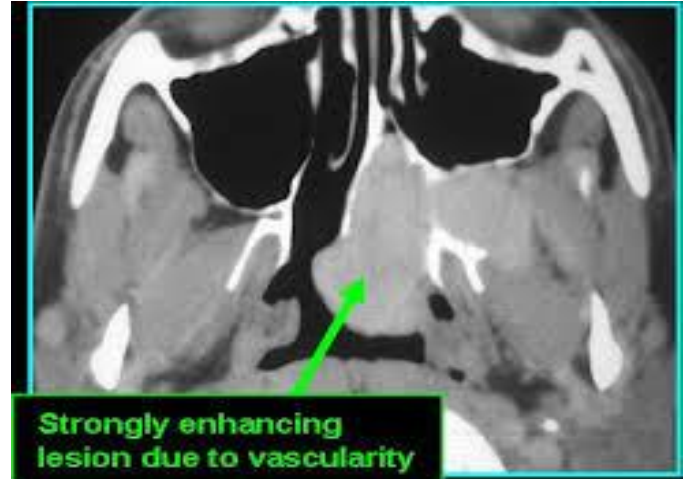


Fig.4 CECT Axial view showing enhancing tumor (JNA) in Pterygopalatine fossa and Nasopharynx

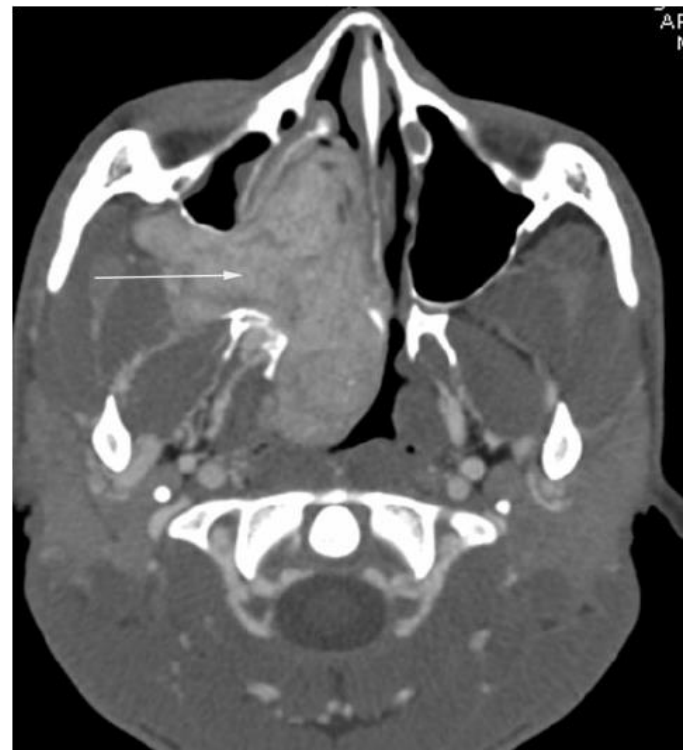

Fig. 5: CECT scan showing large JNA

MRI scan does not identify subtle and initial bony changes and landmarks. However, it is very useful for soft tissues identification and to differentiate between tumor, skull base and bony walls of orbit. MRI usually shows a mass with heterogenous density and flow voids which are due to presence of numerous blood vessels. It results in a

characteristic appearance of salt and pepper which is present in highly vascular tumors. Its signal changes to intermediate density which can be compared to a muscle on T1 images. Its density changes to intermediate to hyper-intense on T2 weighted images. There is enhancement on intravenous contrast^{14,15}(Figures 6,7 and 8).

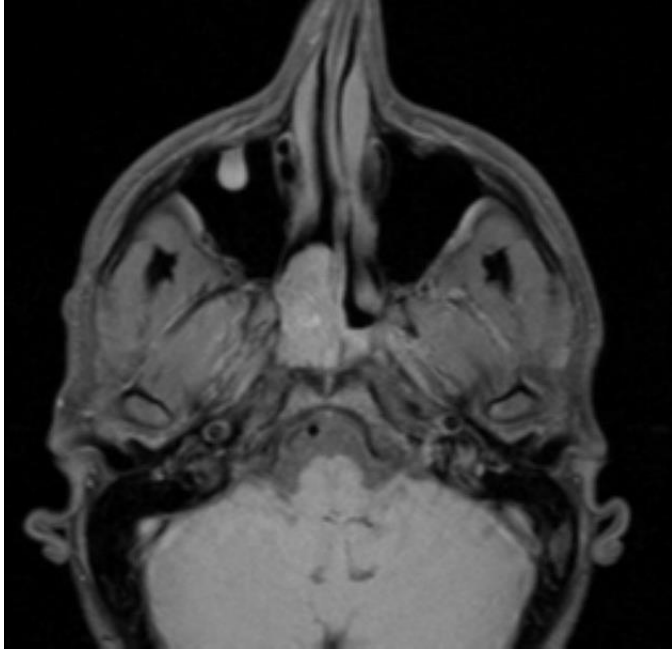


Fig.6 T1 weighted MRI showing intermediate density lesion

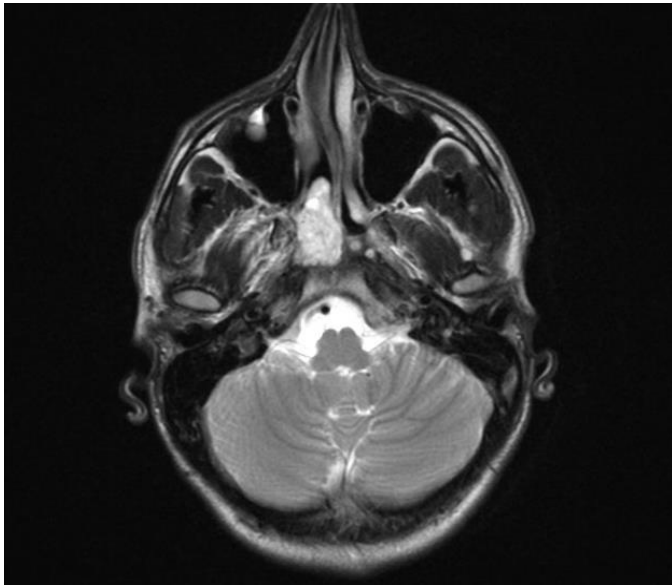


Fig.7 T2 weighted image showing hyperintense signal by JNA

Angiography is used to determine feeding vessels which supply tumor. Most common vessels which give blood supply to JNAs are sphenopalatine artery, internal maxillary artery, palatine arteries, ascending pharyngeal artery, vidian artery, ophthalmic artery and alveolar branches.

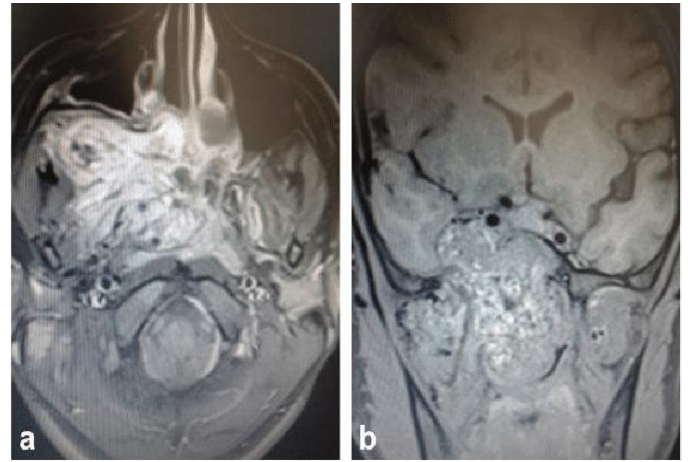


Fig. 8: MRI Axial and Coronal view showing typical salt and pepper appearance of JNA.

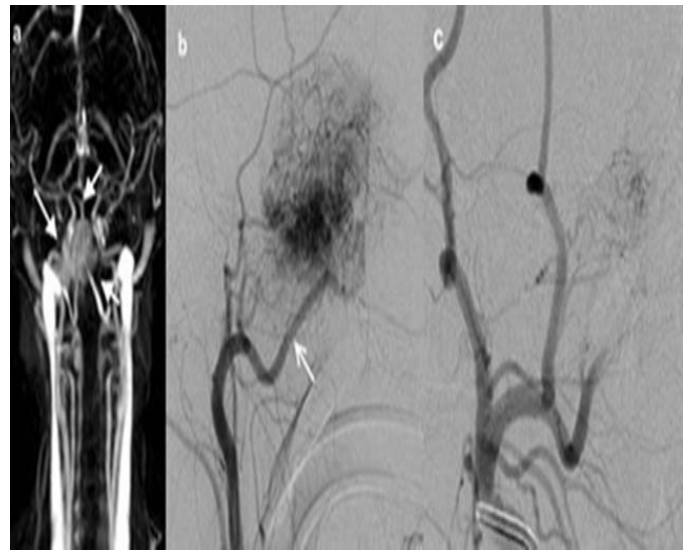


Fig.9: (a) “angiography showing mass on the right with increased vascularity” (white arrows). (b) JNA supplied by right maxillary artery “(white arrow)”. (c) Disappearance of blush after embolization

Bilateral blood supply has been seen in many Angiofibromas due to which few surgeons advise bilateral carotid angiography¹⁶. It's very important to note the angiography is not a diagnostic investigation rather it's a treatment adjuvant with embolization. Preoperative embolization is carried out preoperatively in most centers. However, it is debatable. Some surgeons advise that embolization is not necessary before surgery. It is justified only in big tumors which cause shrinkage and hence complete removal of tumor. However, embolization does not ensure less intra-operative bleeding. Disadvantage of embolization is that tumor shrinkage causes surgical margins to become obscure and thus recurrence rates increase.^{17,18} Another unconventional method is direct tumor puncture which is possible through angiography¹⁹. Biopsy of tumor for its diagnosis is not recommended as it may cause profuse bleeding. Also, tumor is easily diagnosed with clinical examination and imaging thus making biopsy

unnecessary and risky. Once tumor is removed en-block then histopathological examination is performed.

STAGING OF ANGIOFIBROMA

Staging of Angiofibromas is usually done by its extent on imaging (CT and/or MRI). Surgical approach is decided by tumor stage. Most common classification systems are Fisch²⁰ and Radkowski²¹.

Radkowski staging system of JNA

Stage	Tumor Extension
IA	Tumor only in Nose and/or Nasopharynx
IB	Tumor involving one or more sinuses
IIA	Small tumor in Pterygopalatine Fossa
IIB	Tumor involving all pterygopalatine fossa with or without erosion of orbital apex
IIC	Tumor extending to Infratemporal Fossa with extension posterior to pterygoid plates
IIIA	Tumor causing Erosion of the skull base with minimal intracranial extension
IIIB	Tumor causing erosion of the skull base with extensive intracranial extension with or without cavernous sinus involvement

Fisch staging system of JNA

Stage	Tumor Extension
I	Limited to Nasopharynx with negligible bone destruction or limited to the sphenopalatine foramen.
II	Invasion of pterygopalatine fossa or any para nasal sinus with bone destruction.
IIIA	Invasion of infratemporal fossa or orbital region without intracranial involvement.
IIIB	Invasion of infra temporal fossa or orbital region with intracranial extradural (parasellar) involvement.
IVA	Intracranial intradural invasion without involvement of cavernous sinus, pituitary fossa, or optic chiasma.
IVB	Intracranial intradural invasion with involvement of cavernous sinus, pituitary fossa, and optic chiasma.

Treatment: Best treatment option is surgery. Surgical approach is planned by tumor extension, its classification, surgical expertise, availability of endoscopic facility and patient choice.

Surgery by Endoscopic Method: It is considered to be a safe and very effective method to remove angiofibromas. Now with modern endoscopic facilities large tumors like Radkowski type IIIA and those which involve orbit, infratemporal fossa and parasellar region can be removed with endoscopic approach.²² Endoscopic method has the advantage of better visualization of tumor and its margins and minimal need for blood transfusion. It also is advantageous due to shorter duration of surgery, minimal

effect on craniofacial growth and less complications.²³ Dissection is done in sub-periosteal and sub-mucosal plane and then tumor removed en-block through oral route. Another unique technique is to keep tumor in gauze soaked in a vasoconstrictor, this helps to dissect tumor in a relatively bloodless field.²⁴ Some structures of nose are removed for better access and dissection which include nasal septum, posterior wall of maxillary sinus, turbinates and some part or whole of lateral nasal valve. Sometimes a septectomy is done by removing some part of nasal septum anteriorly to create a septal window and facilitate instrumentation from other nasal cavity using a four handed technique.²⁵ If only endoscopic approach is used for removal of JNA then a very short hospital stay is required.

Open approach: A variety of open approaches are being used since early period of JNA surgery till modern era. Few of these techniques commonly used are Midfacial Degloving approach, lateral rhinotomy, transpalatal approach, Le Fort osteotomies and infratemporal fossa approach.²⁶ There are some cases where large tumors in advanced stage are removed by combined open and endoscopic approaches.²⁷

Radiotherapy: Very large and unresectable and recurrent tumors are treated by radiotherapy using lower dose (30-36 Gy). This technique has a good tumor control and reasonably accepted morbidity²⁸. Radiotherapy sometimes results in long term complications which include growth retardation, cataract formation and osteoradionecrosis.

Few cases of residual or recurrent tumor are treated by Gamma knife surgery. Among these cases are tumors which are unresectable due to cavernous sinus or orbital involvement.^{29, 30} In rare cases there is spontaneous involution or regression of tumor in older patients. This was associated with changes in hormones or androgen receptors after adolescence, as this tumor is thought to be androgen dependant.^{31,32}

Conclusion: With our experience we concluded that in early stage JNAs surgery with endoscopic approach was safe and effective treatment. In late-stage disease combined endoscopic and conventional open approaches were best mode of treatment especially with the help of preoperative embolization.

ETHICAL APPROVAL

The study was approved by the Ethical Research Review Committee of Postgraduate Medical Institute / Ameer-ud-Din Medical College/Lahore General hospital, Lahore via Research No. 00-100-21 Dated: April 07, 2021.

REFERENCES

1. Friedberg SA. Vascular fibroma of the nasopharynx (nasopharyngealfibroma) ArchOtolaryngol. 1940;31:313-326.
2. The nature of juvenile nasopharyngeal angiofibroma.Liang J, Yi Z, Lianq P Otolaryngol Head Neck Surg. 2000 Oct; 123(4):475-481

3. Schick B (2009) Current aspects of angiofibroma. *ENT News* 17(6):67–69
4. Flint P, Haughey B, Lund V, Niparko J, Robbins K. *Cummings Otolaryngology: Head and Neck Surgery*. 6th Edition. Saunders; 2014.
5. Tewfik TL, Al Garmi MA. Juvenile Nasopharyngeal Angiofibroma Treatment & Management. Medscape. Available from: <https://emedicine.medscape.com/article/872580-treatment>.
6. Stokes SM, Castle JT. Nasopharyngeal angiofibroma of the nasal cavity. *Head Neck Pathol*. 2010;4(3):210-213.
7. Zhang M, Sun X, Yu H, Hu L, Wang D. Biological distinctions between juvenile nasopharyngeal angiofibroma and vascular malformation: an immunohistochemical study. *Acta Histochem*. 2011;113(6):626-630.
8. Liang J, Yi Z, Liang P. The nature of juvenile nasopharyngeal angiofibroma. *Otolaryngol Head Neck Surg*. 2000;123(4):475-481.
9. Hwang HC, Mills SE, Patterson K, Gown AM. Expression of androgen receptors in nasopharyngeal angiofibroma: an immunohistochemical study of 24 cases. *Mod Pathol*. 1998;11(11):1122-1126.
10. Pernick N. Nasopharyngeal angiofibroma. *Pathology Outlines*. <http://www.pathologyoutlines.com/topic/nasalangiofibroma.html>.
11. Klatt EC. Robbins and Cotran Atlas of Pathology. 1st Edition. Elsevier Saunders; 2006, p.144.
12. Ikubor JE, Okolugbo NE, Okhaku AL. Radiological features of juvenile nasopharyngeal angiofibroma. *J West Afr Coll Surg*. 2013;3(4):84–91.
13. Mishra S, Praveena NM, Panigrahi RG, Gupta YM. Imaging in the diagnosis of juvenile nasopharyngeal angiofibroma. *J Clin Imaging Sci*. 2013;3(Suppl 1)
14. Alimli AG, Ucar M, Oztunali C, Akkan K, Boyunaga O, Damar C, et al. Juvenile nasopharyngeal angiofibroma: magnetic resonance imaging findings. *Journal of the Belgian Society of Radiology*. 2016;100(1):63.
15. Som PM, Curtin HD. *Head and Neck Imaging, Volume 1* und. Mosby; 2003.
16. Wu AW, Mowry SE, Vinuela F, Abemayor E, Wang MB. Bilateral vascular supply in juvenile nasopharyngeal angiofibromas. *Laryngoscope*. 2011;121(3):639-643.
17. Moulin G, Chagnaud C, Gras R, Gueguen E, Dessi P, Gaubert JY, et al. Juvenile nasopharyngeal angiofibroma: comparison of blood loss during removal in embolized group versus nonembolized group. *Cardiovasc Intervent Radiol*. 1995;18(3):158-161.
18. Petruson K, Rodriguez-Catarino M, Petruson B, Finizia C. Juvenile nasopharyngeal angiofibroma: long-term results in preoperative embolized and non-embolized patients. *Acta Otolaryngol*. 2002;122(1):96-100.
19. Elhammady MS, Johnson JN, Peterson EC, Aziz-Sultan MA. Preoperative embolization of juvenile nasopharyngeal angiofibromas: transarterial versus direct tumoral puncture. *World Neurosurg*. 2011;76(3-4):328-34; discussion 263-265.
20. Andrews JC, Fisch U, Valavanis A, Aeppli U, Makek MS. The surgical management of extensive nasopharyngeal angiofibromas with the infratemporal fossa approach. *Laryngoscope*. 1989;99(4):429–437.
21. Radkowski D, McGill T, Healy GB, Ohims L, Jones DT. Angiofibroma. Changes in staging and treatment. *Arch Otolaryngol Head Neck Surg*. 1996;122(2):122-129.
22. Ardehali MM, Samimi SH, Bakhshae M. An effective technique for endoscopic resection of advanced stage angiofibroma. *Iran J Otorhinolaryngol*. 2014;26(74):25–30.
23. Godoy MD, Bezerra TF, Pinna FdeR, Voegels RL. Complications in the endoscopic and endoscopic-assisted treatment of juvenile nasopharyngeal angiofibroma with intracranial extension. *Braz J Otorhinolaryngol*. 2014;80(2):120-125.
24. Vuzitaz A, Manea C. Juvenile Nasopharyngeal Angiofibroma Literature Review and Case Series. *Romanian Journal of Rhinology*, Volume 8, No. 29, January-March 2018
25. Zimmermann E, Selonke I, Gavazzoni FB, Pereira RG, Machado, Tanamati TK, et al. Endoscopic surgery of nasopharyngeal angiofibroma. *Int Arch Otorhinolaryngol*. 2010;14(2):206-211.
26. R Meher, N Arora, EK Bhargava, R Juneja. Massive juvenile nasopharyngeal angiofibroma: ode to the open surgical approach. *Case Reports 2017-casereports.bmj.com*
27. Gupta R, Agarwal SP. Juvenile Nasopharyngeal Angiofibroma: Combined Approach for Excision, Transpalatal and Endoscopic; A New Perspective. *Indian J Otolaryngol Head Neck Surg*. 2018 Mar; 70(1): 125–129.
28. McAfee WJ, Morris CG, Amdur RJ, Werning JW, Mendenhall WM. Definitive radiotherapy for juvenile nasopharyngeal angiofibroma. *Am J Clin Oncol*. 2006;29(2):168-170.
29. Roche PH, Paris J, Regis J, Moulin G, Zanaret M, Thomassin JM, et al. Management of invasive juvenile nasopharyngeal angiofibromas: the role of a multimodality approach. *Neurosurgery*. 2007;61(4):768-777.
30. Park CK, Kim DG, Paek SH, Chung HT, Jung HW. Recurrent juvenile nasopharyngeal angiofibroma treated with gamma knife surgery. *J Korean Med Sci*. 2006;21(4):773-777.
31. Tosun F, Onerci M, Durmaz A, Ugurel S. Spontaneous involution of nasopharyngeal angiofibroma. *J Craniofac Surg*. 2008;19(6):1686-1689.
32. Weprin LS, Siemers PT. Spontaneous regression of juvenile nasopharyngeal angiofibroma. *Arch Otolaryngol Head Neck Surg*. 1991;117(7):796-799

AUTHOR'S CONTRIBUTIONS

AN: Manuscript writing, Editing

MI, GDK: Data collection, Editing

MI: Literature research

RA: Proof reading

MT: Editing, Supervision, guidance