

COMPARISON OF FUNCTIONAL OUTCOME OF SURGICAL TREATMENT OF RECURRENT ANTERIOR SHOULDER DISLOCATION

MUHAMMAD ZAFAR IQBAL, MEHRAN KHAN, MUHAMMAD ADNAN SHAHID KHAN, USMAN LATIF
Services Institute of Medical Sciences/Services Hospital, Lahore

ABSTRACT

Objective: To compare the functional outcome of two different treatment modalities (latarjet & Bristow procedure and Bankart Repair) in recurrent anterior shoulder dislocation

Methods: It was a randomized clinical trial held from December 2017 to December 2018. A total no of 40 patients with age 18-30 years both male and female having recurrent anterior dislocation of shoulder were included in the study. Patients with ligamentous laxity, psychological ailment and global instability were excluded from the study. Patients were divided in two groups having 20 patients in each group. Detailed history, clinical examination, radiographs, CT scan and MRI was completed to establish the diagnosis of recurrent anterior shoulder dislocation. We performed Bristow latarjet procedure in group A and Bankart repair in group B. All patients were followed at 1st, 2nd, 3rd, 4th, 6th week and then at 4th, 6th and 9 months clinically and radiologically to assess the Instability and mobility by using Rowe score.

Results: In group A, there were 16 males and 4 females while in group B were 17 males and 3 females. Mean age in group A was 26.7 years (18-30) while in group B was 27 years (18-29). Right shoulder was involved in 13 (65%) patients in group A and 15 (75%) in group B. Left shoulder was involved in 7 (35%) patients of Group A and 5 (25%) of group B. In group A 18 patients had excellent results, one patient was having grade I subluxation and one patient had positive apprehension test. In group B four patients had recurrence and three patients had subluxation of grade II.

Conclusion: Results of latarjet and Bristow procedure were excellent than Bankart repair. Patient's satisfaction was also better in group A than group B.

Key words: Bankart lesion, Hillsachs lesion, Bristow and latarjet procedure, Bankart repair, Glenohumeral instability

How to cite this article: Iqbal MZ, Khan M, Khan MAS, Latif U. Comparison of functional outcome of surgical treatment of recurrent anterior shoulder dislocation. *Pak Postgrad Med J* 2019;30(2): 78-81.

INTRODUCTION

Shoulder joint is the most mobile joint of the body^{1,2}. Shoulder joint dislocation accounts for the 50% of all the dislocations³. Its incidence is 2 % among general population⁴. In most of the cases it is recurrent shoulder dislocation. In 97% cases of recurrent dislocation it is anterior dislocation^{5,6}. Mechanism for recurrent anterior dislocation is abduction, external rotation and extension⁷. There is persistent inability of tissues to keep the humeral head in glenoid cavity. Glenohumeral instability may be bony or ligamentous⁸. It may result from sudden injury to glenoid cavity (Bankart lesion), proximal humerus (Hillsachs lesion), repetitive micro trauma or as a result of generalized ligamentous laxity^{9,10}.

*Correspondence to: Muhammad Zafar Iqbal, Services Institute of Medical Sciences/Services Hospital, Lahore
E-mail: drzafar2014@gmail.com*

Received: May 15, 2020

Revised: June 15, 2020

Accepted: June 16, 2020

After initial traumatic incidence the glenohumeral joint becomes unstable. Glenoid bone injury (Bankart lesion) is one of the main cause of failed shoulder stabilizing surgeries¹⁰. For success of surgical treatment, bone deficiency or attrition assessment is an important step regarding the pre-operative evaluation¹¹. Radiographic evaluation includes apical oblique, axillary and west point view. MRI and MR arthrographic assessment provides valuable information regarding the soft tissues problem. The extent of bone loss is better delineated by 3D reconstruction CT scan. CT scan provides exact measurement of glenoid bone loss¹².

Once the bone loss estimation is made decision regarding the surgical approach and risk of recurrent instability can be discussed with patient and the family. When glenoid bone loss is 25- 35 % open repair and some sort of bone augmentation procedure is necessary¹³. There are various procedures and techniques for bone augmentation such as iliac crest bone graft, Latarjet and Bristow procedure, Bankart repair and arthroscopic repair of shoulder instability.

In surgical management of glenohumeral instability one should consider the glenoid and humeral head lesions, soft tissue involvement, patient profession and needs of the patient. The choice of procedure depends on the radiographic and MRI findings, available logistics and surgeon experience.

METHODS

This is comparative prospective study conducted at department of orthopaedic surgery services hospital Lahore from December 2017 to December 2018. A total no of 40 patients having recurrent anterior dislocation of shoulder were included in the study. All the patients were admitted through OPD. Patient were divided into two equal groups A and B. All patients had history of trauma regarding the 1st episode of dislocation then followed by non-traumatic episodes. Patients having habitual dislocation due to psychological ailment, posterior recurrent dislocation and global instability were excluded from the study. All patients in both groups underwent thorough history and clinical examination to determine the existence and direction of instability. Clinical tests performed include sulcus test, apprehension test and anterior drawer test. Comparative clinical examination of contralateral shoulder and other joints was done to rule out generalized ligamentous

laxity. Following x-rays were taken true AP view, axillary view and apical oblique view. Bankart and Hillsachs lesion evaluation was done with MRI and MR arthrogram. Assessment of size of bony Bankart lesion was done with 3D reconstruction CT scan. Informed consent was obtained from all the patients before surgery. We used anterior deltopectoral approach. Patients were kept in polysling and velpeau dressing for 7 days post operatively. On the 7th day velpeau dressing was removed and poly sling was continued. After 7 days pendulum exercises were started under the supervision of physiotherapist. During the 3rd and 4th week postoperatively pendulum exercises were followed by forward flexion up to 90 degree and abduction was started. Patient was followed weekly for the next 6 weeks and functional assessment was done by using Rowe score. The polysling was continued till 6th week. Flexion extension internal and external rotation movements were started after 6 weeks and gradually increased with assistance under physiotherapist supervision. At 4th month contact free sports like running was started along with continued muscle strengthening exercises around the shoulder. After 6 months contact sports were allowed.

Table 1: Rowe Score

Parameters to be assessed	FUNCTION (/50 points)	PAIN (/10 points)	STABILITY (/30 points)	MOBILITY (/10 points)*
1	No limitation in work and sports 50	None 10	No recurrence, subluxation, or apprehension 30	Normal mobility 10
2	No limitation in work, mild limitation in sports 35	Mild 5	Apprehension when placing arm in certain positions 15	<25% loss of normal external rotation,internal rotation and elevation 5
3	Mild limitation in work above head and sports 20	Severe 0	Subluxation (not requiring reduction) 10	>25% loss of normal external rotation,internal rotation and elevation 0

Total score=100, Excellent 90-100, Good 75-89, Average 51-74, Bad <50.

Data was analyzed with SPSS 18. Evaluation of statistical difference for the independent groups was done by using student t test. Acceptable level of significance was chosen by P value more than 0.05.

Table 2: Rowe score results

Group	Excellent: 90-100	Good: 75-89	Average: 51-74	Bad: <50
A	18(90%)	1(5%)	1(5%)	
B	10(50%).	3(15%)	1(5%)	6(30%)

RESULTS:

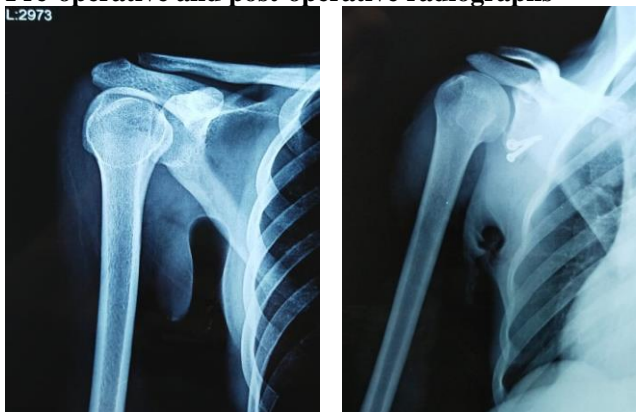
40 patients were included in the study. These patients were divided in two groups A & B having 20 patients in each group. Mean age in group A was 26.7 years while

in group b was 27 years. In group A there were 16 (80%) males and 4 (20%) females while in group B were 17 (85%) males and 3 (15%) females.

Table 3: Age and sex distribution

Age	Group A	Group B
Less than 20	17	18
20 to 40	3	2
Gender		
Male	16	17
Female	4	3

Pre-operative and post-operative radiographs



Right shoulder was involved in 13 (65%) patients in group A and 15 (75%) in group B. Left shoulder was involved in 7 (35%) patients of Group A and 5 (25%) of group B. Time interval between 1st dislocation and surgery on an average was 3.2 years (6 months to 5.5 years). In all patients 1st episode of dislocation was posttraumatic. We performed Bristow laterjet procedure in group A and Bankart repair in group B. Patients were followed for 9 months to see recurrence of dislocation and to see any signs of instability. There was no post-operative recurrent dislocation in group A while in Group B 4 patients had recurrent dislocations after surgery at 4th month. ROWE score was used for recording the mobility, stability, function and pain. In group A ROWE score was > 90 (excellent) in 18 (90%) patients while in group B it was in 10 (50%). Good result (ROWE score 75 to 89) was in 1 (5%) patient in group A while it was 3 (15%) in group B. Average result was seen in 1 (5%) patient in group A and 1 (5%) in group B. Bad result was seen in 6 (30%) patients of group B while no patient reported with bad result in group A.

DISCUSSION

This study was conducted to compare and evaluate the outcome of two different surgical modalities for recurrent shoulder dislocation. Our results in terms of stability, mobility and function of the shoulder joint after the surgery are comparable with current studies. Younger the patient, higher is the chances of recurrent

dislocation¹. Moreover males have higher incidence of recurrent dislocation².

Study of Rowe has also shown that 98% patient having recurrent dislocation are younger than 20 years of age. In another study the risk of recurrence was more in patients who are under the age of 30 years i.e 30%. As the age progresses it decreases to 10% (30 to 40 years). In our study 25 % patients in group A were less than 20 years while remaining patients were in the range of 30 to 40 years. Similar age distribution was seen in group B. In our study trauma was the cause of 1st episode of dislocation. This is also comparable with the study of ROWE¹⁴.

According to Bankart, in case of recurrent shoulder dislocation anatomical reconstruction is the most commonly performed procedure but the opinion differs when the capsular laxity is the major pathology. Here laterjet or bristo procedure is the choice.

The limitation of movement is related to improper capsular tension. During open surgical procedures when the capsular tension is too high, there will be more fibrosis, this will compromise the results. Similar results regarding the stability, limitation of movements and function were seen in group B¹⁰.

Long term results of laterjet procedure efficacy are excellent. We found excellent results with laterjet procedure compared with Bankart repair. The reason is that locally harvested coracoid graft along with conjoint tendon act as extra articular base that provides extension of articular arc of glenoid cavity¹⁵.

Bony block of coracoid serves to extend the glenoid cavity area. When the arm is abducted and externally rotated, conjoint tendon provides the resistance to anterior humeral dislocation. Moreover, the deficient antero-inferior aspect of capsule is resisted by the tenodesis effect of conjoint tendon and coracoid process^{16,17}.

Joshi MA, Young AA et al found that The Latarjet-Patte procedure fulfills the parameters of recurrent anterior dislocation treatment in contact sports players and is considered as procedure of choice in this patient group having excellent results in 88%¹⁹. This result was comparable with our study.

Study of Hovelius has satisfactory results in 98% patients with Bristo procedure in recurrent shoulder dislocation¹⁸. Similar results have been shown in our study.

So there are many variables which have effects on the outcome of surgery like age, gender, shoulder dominance, no of dislocations prior to surgery, underlying pathology i.e capsular laxity, surgical procedures, rehabilitation program and proper follow-up.

CONCLUSION

This study depicts that Bristow & Latarjet procedure has better outcome in terms of stability, mobility and improvement in overall function of the patient with recurrent anterior shoulder dislocation. Moreover patient satisfaction was excellent in this group post-operatively.

This technique must be considered as preferred mode of treatment for anterior shoulder instability.

ETHICAL APPROVAL

The study was approved by the Ethical Review Committee of Services Institute of Medical Sciences, Lahore, Pakistan vide reference No. 418/17 dated 30 November, 2017.

REFERENCES

- 1 Cowan PT, Mudreac A, Varacallo M. StatPearls [Internet]. StatPearls Publishing; Treasure Island (FL): May 24, 2020. Anatomy, Back, Scapula.
- 2 Rugg CM, Hettrich CM, Ortiz S, Wolf BR, MOON Shoulder Instability Group. Zhang AL. Surgical stabilization for first-time shoulder dislocators: a multicenter analysis. *J Shoulder Elbow Surg.* 2018 Apr;27(4):674-685.
- 3 Enger M, Skjaker SA, Melhuus K, Nordsletten L, Pripp AH, Moosmayer S, et al. Shoulder injuries from birth to old age: A 1-year prospective study of 3031 shoulder injuries in an urban population. *Injury.* 2018 Jul;49(7):1324-1329.
- 4 Gottschalk LJ, Walia P, Patel RM, Kuklis M, Jones MH, Fening SD, et al. Stability of the Glenohumeral Joint With Combined Humeral Head and Glenoid Defects: A Cadaveric Study. *Am J Sports Med.* 2016 Apr;44(4):933-940.
- 5 Cofield RH, Kavanagh BF, Frassica FJ. Anterior shoulder instability. *Instr Course Lect.* 1985;34:210-227.
- 6 Walton J, Paxinos A, Tzannes A, Callanan M, Hayes K, Murrell GA. The unstable shoulder in the adolescent athlete. *Am J Sports Med.* 2002 Sep-Oct;30(5):758-767.
- 7 Crichton J, Jones DR, Funk L. Mechanisms of traumatic shoulder injury in elite rugby players. *Br J Sports Med* 2012;46:538-542.
- 8 Yanagawa T, Goodwin CJ, Shelburne KB, Giphart JE, Torry MR, Pandey MG. Contributions of the individual muscles of the shoulder to glenohumeral joint stability during abduction. *J Biomech Eng* 2008;130:021024
- 9 Spatschil A, Landsiedl F, Anderl W. Posttraumatic anterior-inferior instability of the shoulder: arthroscopic findings and clinical correlations. *Arch Orthop Trauma Surg* 2006;
- 10 Sugaya H, Moriishi J, Dohi M, Kon Y, Tsuchiya A. Glenoid rim morphology in recurrent anterior glenohumeral instability. *J Bone Joint Surg [Am]* 2003;85:878-884.
- 11 Nacca C, Gil JA, Badida R, Crisco JJ, Owens BD. Critical glenoid bone loss in posterior shoulder instability. *Am J Sports Med* 2018; 46:1058-1063.
- 12 Gerber C, Nyffeler RW. Classification of glenohumeral joint instability. *Clin Orthop Relat Res* 2002;400:65-76
- 13 Di Giacomo G, Piscitelli L, Pugliese M. The role of bone in glenohumeral stability. *EFORT Open Rev.* 2018;3(12):632-640. Published 2018 Dec 20. doi:10.1302/2058-5241.3.180028
- 14 Rowe CR, Zarins B. Recurrent transient subluxation of the shoulder. *J Bone Joint Surg Am.* 1981;63:863-872.
- 15 McHale, Kevin J et al. "Latarjet Technique for Treatment of Anterior Shoulder Instability With Glenoid Bone Loss." *Arthroscopy techniques* vol. 6,3 e791-e799. 19 Jun. 2017,
- 16 Moon S.C., Cho N.S., Rhee Y.G. Quantitative assessment of the Latarjet procedure for large glenoid defects by computed tomography: A coracoid graft can sufficiently restore the glenoid arc. *Am J Sports Med.* 2015;43:1099-1107
- 17 Yamamoto N., Muraki T., An K.N. The stabilizing mechanism of the Latarjet procedure: A cadaveric study. *J Bone Joint Surg Am.* 2013;95:1390-1397
- 18 Hovelius L, Sandström B, Olofsson A, Svensson O, Rahme H. The effect of capsular repair, bone block healing, and position on the results of the Bristow-Latarjet procedure (study III): long-term follow-up in 319 shoulders. *J Shoulder Elbow Surg.* 2012;21(5):647-660.
- 19 Joshi MA, Young AA, Balestro JC, Walch G. The Latarjet-Patte procedure for recurrent anterior shoulder instability in contact athletes. *Clin Sports Med.* 2013 Oct;32(4):731-9. doi: 10.1016/j.csm.2013.07.009. PMID: 24079431.

AUTHORS' CONTRIBUTION:

MZI: Concept, supervision, critical review

MK: Manuscript writing, data analysis

MASK: Data collection

UL: Data collection, data analysis