

# OUTCOME OF OPEN SEPTORHINOPLASTY AMONG PATIENTS WITH NASAL OBSTRUCTION AND EXTERNAL NASAL DEFORMITY

MUHAMMAD ILYAS, MAZHAR IFTIKHAR, RIZWAN AKBAR BAJWA, NAJAM UL HASNAIN KHAN

## ABSTRACT

**Background:** Open septorhinoplasty is most common procedure carried out in the ENT basic setup. It is performed to relieve the nasal obstruction and to get better aesthetic appearance.

**Objective:** The objective of the study was to assess the nasal patency and cosmetic improvement among patients.

**Method:** It was cross-sectional descriptive study in which 100 patients with nasal obstruction and external nasal deformity visiting ENT Department of Lahore General Hospital Lahore were included. Data was collected through questionnaire, which was entered into computer using SPSS software version 20.0.

**Results:** Among 100 patients, 57.0% were males and 48.0% were 21-25 years old. Among these patients, 100.0% had nasal blockage and external deformity. After septorhinoplasty, 94.0% patients had complete improvement in nasal blockage and 95.0% patients had improved external deformity.

**Conclusion:** Study concluded that 94.0% patients had complete improvement in nasal blockage and 95.0% patients in external deformity. Septorhinoplasty is a useful surgical procedure and should be used in health care facilities.

**Keywords:** Septorhinoplasty, nasal obstruction, external deformity.

## INTRODUCTION

Nose is considered most prominent feature of face<sup>[1]</sup> because its appearance is definitely associated with beauty as well as personality. Open septorhinoplasty is an important cosmetic surgery done by otorhinolaryngologists.<sup>[2]</sup>

Nasal obstruction is a most frequent dilemma in the otolaryngology practice which can occur due to various factors.<sup>[3]</sup> The causes of nasal obstruction are divided in two components namely fixed and dynamic. The fixed components may require surgical repair while dynamic components can be treated medically. Most frequent fixed anatomic components leading to blockage of nasal airway is deviated nasal septum while nasal valve concede like major cause of nasal airway blockage has been documented properly.<sup>[4]</sup>

In numerous population settings, nasal obstruction is believed a significant public complaint.<sup>[5]</sup> Virtually 33% patients who go to otolaryngologist have nasal obstruction and among these patients twenty five percent looking for surgical intervention.<sup>[6]</sup>

In medical literature, nasal deviation is described as “deviated nose” a difficult deformity involving about complete structure inside the nose. Crooked or deviated nose, can be identified through drawing a line almost drawn from the mid-glabella to the pogonion, goes through nasal tip, cupid's bow, nasal bridge and lastly

incisive teeth, nasal divergence from this line to the other side, could be described like deviated nose.<sup>[7]</sup>

Anatomically, the nasal deviation could be classified into following deformities: “C-shaped deformity”, “S-shaped deformity” and “tilt deformity” or a mixture of them.<sup>[7]</sup>

Etiologically, the deviated nose is approximately always due to nasal trauma; however, most of these deformities devoid of recognized causing trauma are wrongly referred to like evolutionary or congenital deformities; now it is thought that such deviations occur owing to small fractures during infancy or obstetric traumas, early childhood and intrauterine life. No matter what the deviated nose cause is, such deformity precipitates in the structural irregularity causing various difficulties to either or the both nasal function and aesthetic. This reality ensures that surgical intervention is required.<sup>[7]</sup>

Septorhinoplasty addresses nasal obstruction fixed component owing to anatomical deformities which failed medical therapy caused by nasal valve deficiency. Rhinomanometry carried out preoperatively and postoperatively among 160 patients demonstrated modest improvement in the mean nasal airflow by septoplasty alone, while internal and external valvular reconstruction caused further significant improvement in the nasal airflow. A considerable improvement was observed among patients who experienced

septorhinoplasty (septoplasty combination with reconstruction of external and internal valvular).<sup>[4]</sup>

Deviated nose is a regular abnormality encountered during septorhinoplasty, and still it is most challenging and difficult pathology to treat, for even those surgeons who are well experienced. During deviated nose rectification, disappointing aesthetic results causes high rates of failure and revision. Most of the surgeons think that chance of unsatisfactory result is associated with deviation type. Though, some studied have evaluated the outcomes of broad case series and examined success rates as per types of the deviated nose.<sup>[8]</sup>

Surgery outcome assessment measured by the patient's satisfaction or QoL (quality of life) is much significant, particularly in the plastic surgery.<sup>[9]</sup> It is truth that both function and aesthetic hold their own values, one offers a better QoL and other offers better self-image.<sup>[7]</sup> Mostly the open septorhinoplasty is a procedure carried out in the ENT basic setup. For the septorhinoplasty procedures, there are varied indications, for example, to provide better aesthetic appearance and to ease nasal obstruction.

Therefore, septorhinoplasty is done to improve the QoL by relieving nasal obstructions and it offers better aesthetic appearance by providing better shape of nose.<sup>[2]</sup>

Present study aims to assess the nasal patency and cosmetic improvement among patients visiting ENT Department of Lahore General Hospital Lahore.

## MATERIAL AND METHODS

It was cross-sectional descriptive study in which 100 patients with nasal obstruction and external nasal deformity visiting ENT Department of Lahore General Hospital Lahore were included. Data was collected through questionnaire, which was entered into computer software using SPSS 20.0. Confidentiality of the data was ensured and proper consent was obtained before data collection.

## RESULTS

Table-1 describes that among 100 patients, 57 (57.0%) were males and 43 (43.0%) were female patients.

As far as age of the patients is concerned, 17 (17.0%) were 18-20 years old and 48 (48.0%) were 21-25 years old while 35 (35.0%) patients were 26-30 years old. The mean age of the patients was  $23.3 \pm 4.5$  years.

Table-2 demonstrates numerous complaints among patients and found that 100 (100.0%) patients had nasal blockage and external deformity while 59 (59.0%) patients had headache, 67 (67.0%) loss of smell, 78 (78.0%) postnatal drip and 55 (55.0%) patients had

pharyngitis.

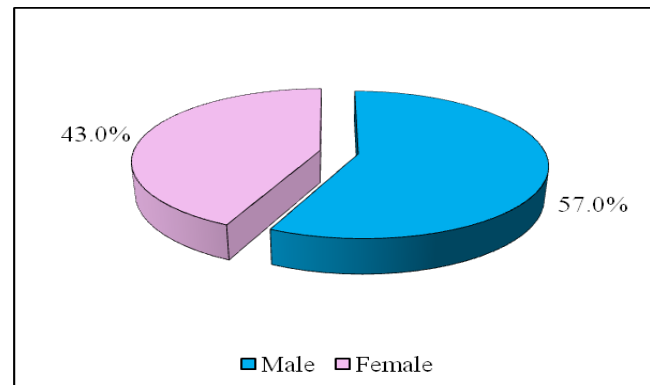
Table-3 depicts that among 100 patients, 94 (94.0%) had complete improvement in nasal blockage after treatment and only 6 (6.0%) required further treatment.

Likewise among 100 patients, 95 (95.0%) patients had improvement in external deformity after treatment and only 5 (5.0%) had some problem.

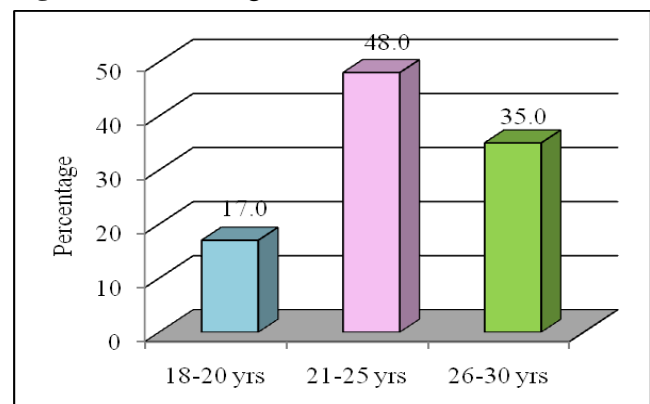
**Table 1:** Patients' profile

	Frequency	Percentage (%)
<b>Sex</b>		
Male	57	57.0
Female	43	43.0
Total	100	100.0
<b>Age</b>		
18-20 years	17	17.0
21-25 years	48	48.0
26-30 years	35	35.0
Total	100	100.0
Mean $\pm$ SD	23.3 $\pm$ 4.5	

**Figure 1:** Patients' sex



**Figure-2:** Patients' age



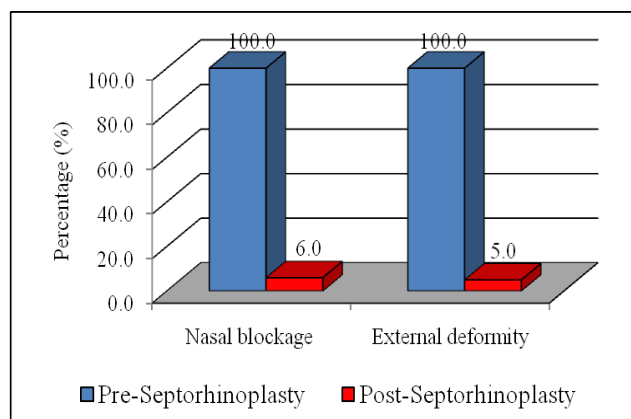
**Table 2:** Presenting complaints (n=100)

	Yes	No
Nasal blockage	100 (100.0%)	0 (0.0%)
External deformity	100 (100.0%)	0 (0.0%)
Headache	59 (59.0%)	41 (41.0%)
Loss of smell	67 (67.0%)	33 (33.0%)
Postnasal drip	78 (78.0%)	22 (22.0%)
Pharyngitis	55 (55.0%)	45 (45.0%)

**Table-3:** Surgical outcome (n=100)

	Yes	No
Nasal blockage	6 (6.0%)	94 (94.0%)
External nasal deformity	5 (5.0%)	95 (95.0%)

**Figure-3:** Pre- and Post-septorhinoplasty regarding nasal blockage & external deformity



## DISCUSSION

Nasal obstruction and external deformity are leading public health problems that exacerbate the quality of life and aesthetic appearance of the people. Present study assessed the nasal patency and cosmetic improvement among patients. To acquire adequate results, one hundred patients were included in the study and found that more than half (57.0%) of the patients were males and 43.0% were females patients. The findings of our study are comparable with a recent study conducted by Chavan and coworkers (2017) who also reported that most of the patients (55.0%) were males and 45.0% were females.<sup>[2]</sup>

During the period of young age, people are more concerned about their appearance and want to look more attractive. It is important to mention that significant majority (65.0%) of patients was 18-25 years old while 35.0% patients were 26-30 years old. The mean age of the patients was  $23.3 \pm 4.5$  years. A study carried out in India by Zahedi and Hussain (2016)

demonstrated that mean age of the patients was  $28.7 \pm 11.3$ .<sup>[4]</sup>

When presenting complaints were assessed among patients, study indicated that 100.0% patients had nasal blockage and external deformity while headache, loss of smell, postnasal drip and pharyngitis were observed among 59.0%, 67.0%, 78.0% and 55.0% patients, respectively. But the results of a study undertaken by Alotaibi (2017) indicated that most of the patients (94.0%) had nasal obstruction, breathing trouble (87.0%), sleeping trouble (84.0%), nasal congestion (83.2%), exercise problem (71.0%), and other complications (3.8%).<sup>[5]</sup>

Study showed very encouraging results that after treatment, 94.0% patients had complete improvement in nasal blockage and 95.0% patients had improvement in external deformity. There were only 6.0% and 5.0% patients who required further surgical intervention regarding nasal blockage and external deformity, respectively. The results of our study exhibited better scenario than the study performed by Alotaibi (2017) who confirmed that nasal blockage was completely improved among 70.7% patients.<sup>[5]</sup> Likewise Cho and teammates (2013) reported in their study that external deformity was improved among 80.2% patients.<sup>[8]</sup>

## CONCLUSION

Study concluded that 94.0% patients had complete improvement in nasal blockage and 95.0% patients in external deformity. Open septorhinoplasty is a useful surgical procedure and should be used in health care facilities. Further studies are required to be conducted on large scale to assess the nasal patency and cosmetic improvement among patients to improve their quality of life and aesthetic appearance.

## REFERENCES

1. Kim J, Jung HJ, Shim WS. Corrective septorhinoplasty in acute nasal bone fractures. Clin Exp Otorhinolaryngol. 2018; 11(1): 46-51.
2. Chavan RP, Ingole SM, Birajdar SN. Assessment of surgical outcomes of septorhinoplasty patients: a clinical study. Int J Otorhinolaryngol Head Neck Surg. 2017; 3: 268-72.
3. Kahraman E, Cil Y, Incesulu A. The effect of nasal obstruction after different nasal surgeries using acoustic rhinometry and nasal obstruction symptom evaluation scale. World J Plast Surg 2016; 5(3): 236-43.
4. Zahedi FD, Husain S, Gendeh BS. Functional outcome evaluation of septorhinoplasty for nasal obstruction. Indian J Otolaryngol Head Neck Surg 2016; 68(2): 218-23.

5. Alotaibi A. Quality of life in patients with nasal obstruction after one year of septoplasty. *Res Otolaryngol.* 2017; 6(6): 81-7.
6. Delaney SW. Evolution of the septoplasty: maximizing functional and aesthetic outcomes in nasal surgery. *M J Otol.* 2018; 1(1): 4.
7. Hosseini SMS, Sadeghi M, Saedi B, Safavi A, Hedayati GR. Aesthetic and functional outcomes of open versus closed septorhinoplasty in deviated nose deformity. *Int J Otolaryngol Head Neck Surg.* 2012; 1: 7-13.
8. Cho GS, Jang YJ. Deviated nose correction: different outcomes according to the deviation type. *Laryngoscope.* 2013; 123: 1136-42.
9. Esteves SS, Ferreira MG, Almeida J C, Abrunhosa J, Almeida e Sousa C. Evaluation of aesthetic and functional outcomes in rhinoplasty surgery: a prospective study. *Braz J Otorhinolaryngol.* 2017; 83: 552-7.